

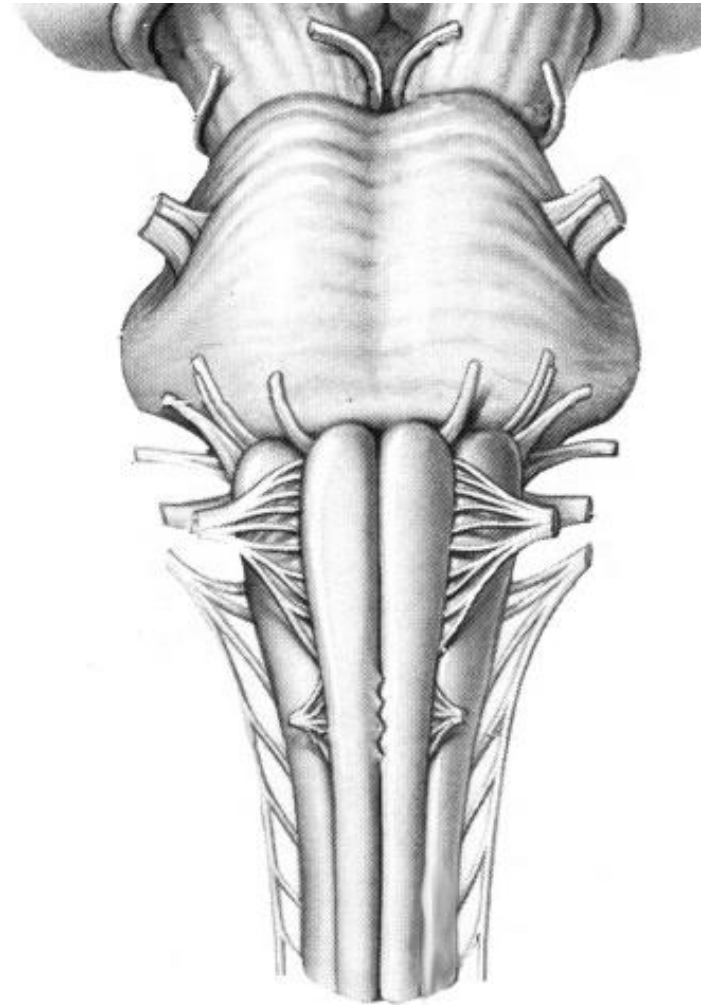
1. Indicate the listed structures on the pictures:

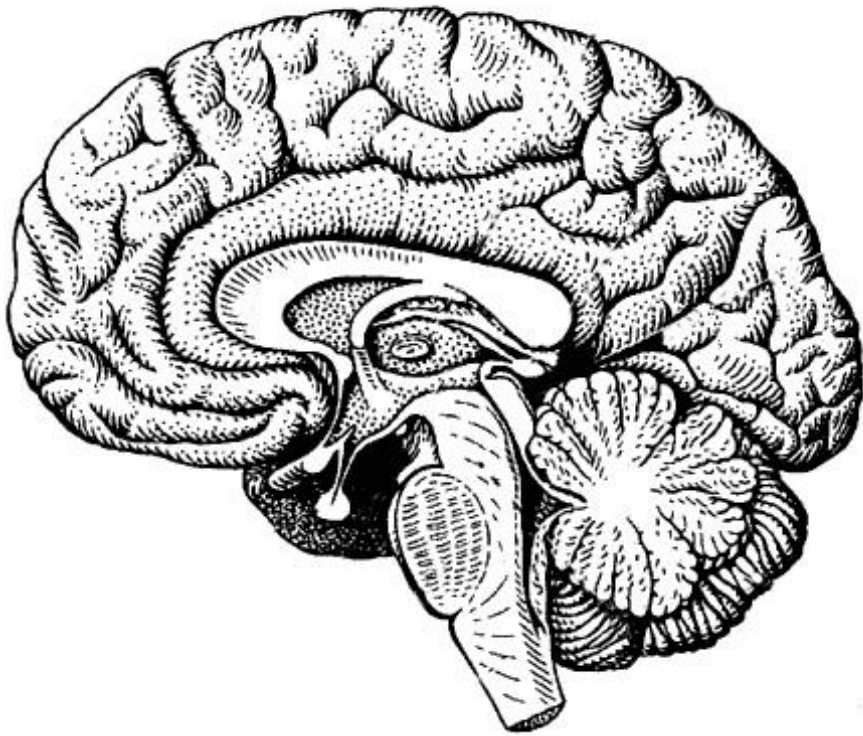
Medulla oblongata:

1. Ventral and dorsal surfaces;
2. Anterior median fissure, *fissura mediana anterior*;
3. Posterior median sulcus, *sulcus medianus posterior*;
4. Pyramid, *pyramis medullae oblongatae*;
5. Pyramidal decussation, *decussatio pyramidum*;
6. Gracile fasciculus, *fasciculus gracilis*;
7. Cuneate fasciculus, *fasciculus cuneatus*;
8. Olive, *oliva*;
9. Anterolateral sulcus, *sulcus anterolateralis*,
10. Posterolateral sulcus, *sulcus posterolateralis*,
11. Roots of the accessory, vagus, glossopharyngeal and hypoglossal nerves
12. Gracile tubercle, *tuberculum gracile*;
13. Cuneate tubercles, *tuberculum cuneatum*;

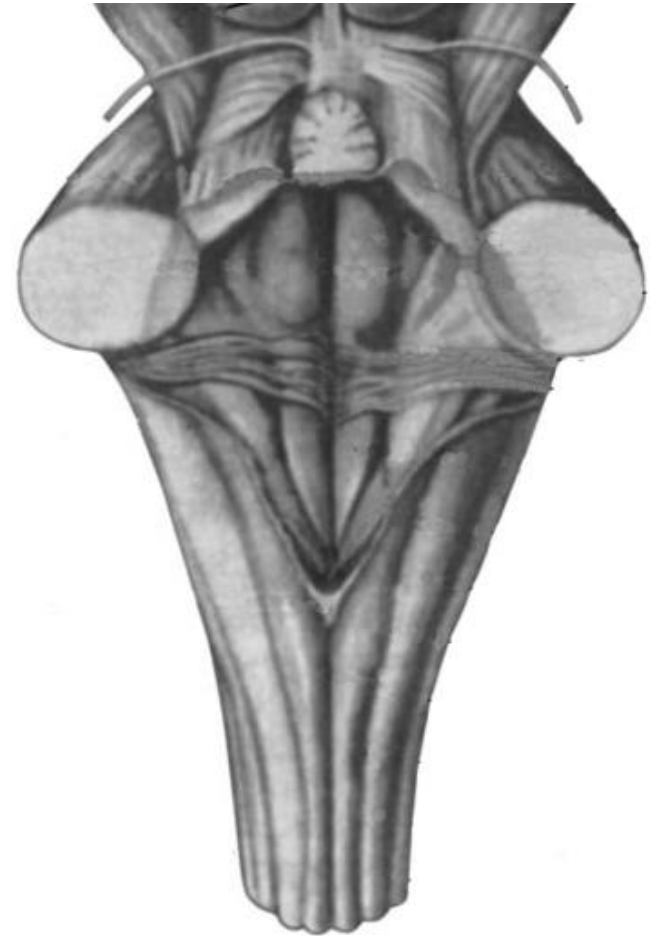
Pons:

14. Ventral and dorsal surfaces;
15. Basilar sulcus, *sulcus basilaris*,
16. Roots of the abducens, facial, vestibulocochlear and trigeminal nerves;
17. Medullopontine sulcus, *sulcus bulbopontinus*;
18. Cerebellopontine angle, *angulus pontocerebellaris*;





The sagittal section of the brain



**The dorsal surface of the medulla oblongata
and pons**

2. Indicate the listed structures of the cerebellum on the pictures:

1. Hemispheres, *hemispheria*;
2. Superior cerebellar peduncles, *pedunculi cerebellares superiores*;
3. Middle cerebellar peduncles, *pedunculi cerebellares medii*;
4. Inferior cerebellar peduncles, *pedunculi cerebellares inferiores*;
5. Superior medullary velum, *velum medullare superius*;
6. Inferior medullary velum, *velum medullare inferius*;
7. Nodulus, *nodulus*;
8. Flocculus, *flocculus*;
9. Peduncle of flocculus, *pedunculus flocculi*;
10. Horizontal fissure, *sulcus horizontalis*;
11. Superior and inferior hemispheric surfaces;
12. Laminae (foliae cerebelli);
13. Middle cerebellar peduncles, *pedunculi cerebellares medii*;

Vermian lobules:

14. Lingula, *lingula cerebelli*;
15. Central lobule, *lobulus centralis*;
16. Monticulus, *monticulus*;
17. Culmen, *culmen*;
18. Declive, *declive*;
19. Folium, *folium cerebelli*;
20. Tuber vermis, *tuber vermis*;
21. Pyramid, *pyramis vermis*;
22. Nodulus, *nodulus*;

Hemispheric lobules:

23. Quadrangular lobule, *lobulus quadrangularis*;
24. Superior semilunar lobule, *lobulus semilunaris superior*;
25. Inferior semilunar lobule, *lobulus semilunaris inferior*;
26. Gracile lobule, *lobulus gracilis*;
27. Biventral lobule, *lobulus biventer*;
28. Cerebellar tonsil, *tonsilla cerebelli*;

