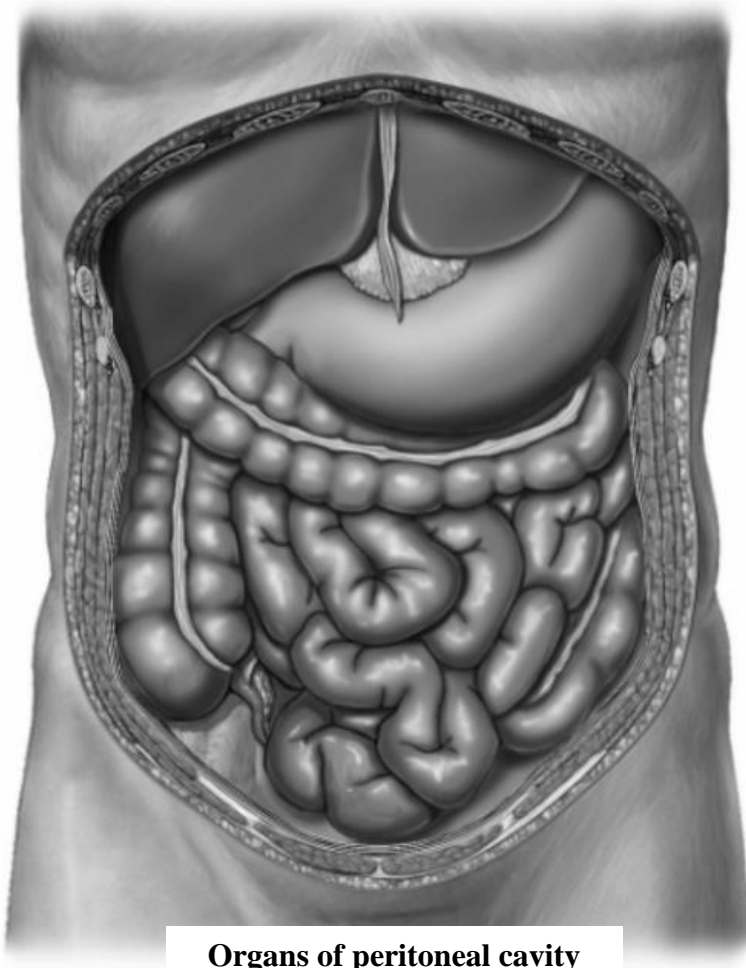
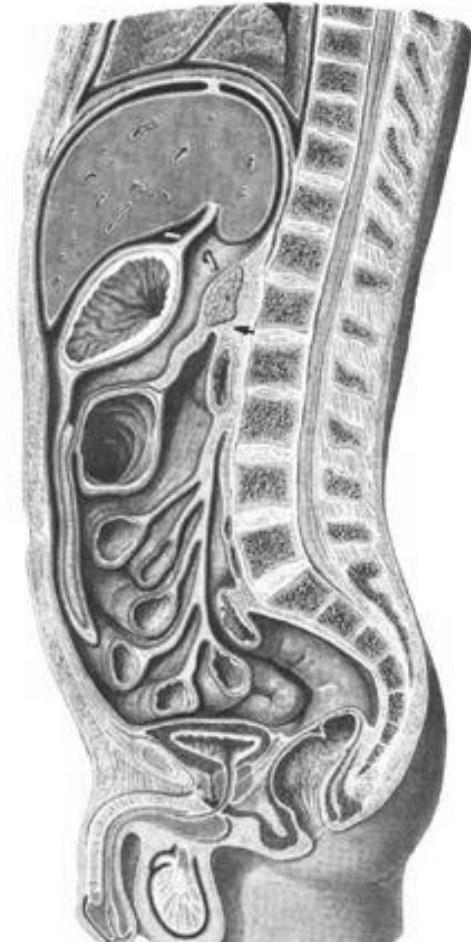

Task 28: Mark with lines the storeys of the peritoneal cavity on the following picture.



**Organs of peritoneal cavity
(anterior aspect)**

**Task 29: Mark with colored lines:
the abdominal cavity and peritoneal cavity;
retroperitoneal space, anteperitoneal space and
subperitoneal space.**



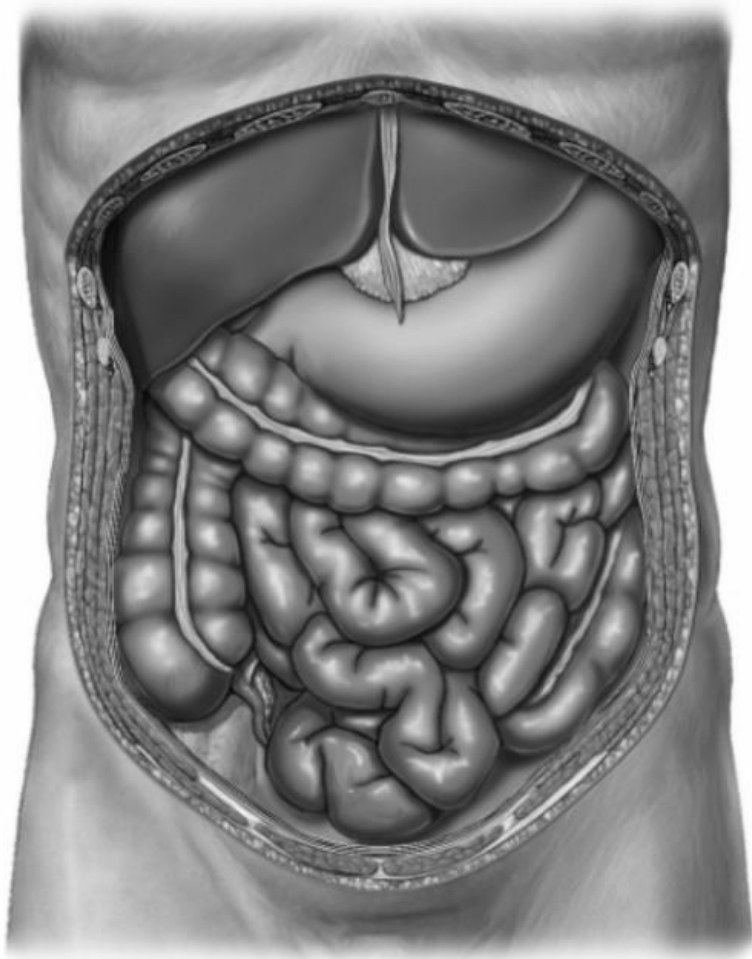
**Organs of abdominal
cavity
(sagittal aspect)**

Task 30: Complete the table (put the names of the listed organs into the corresponding windows)

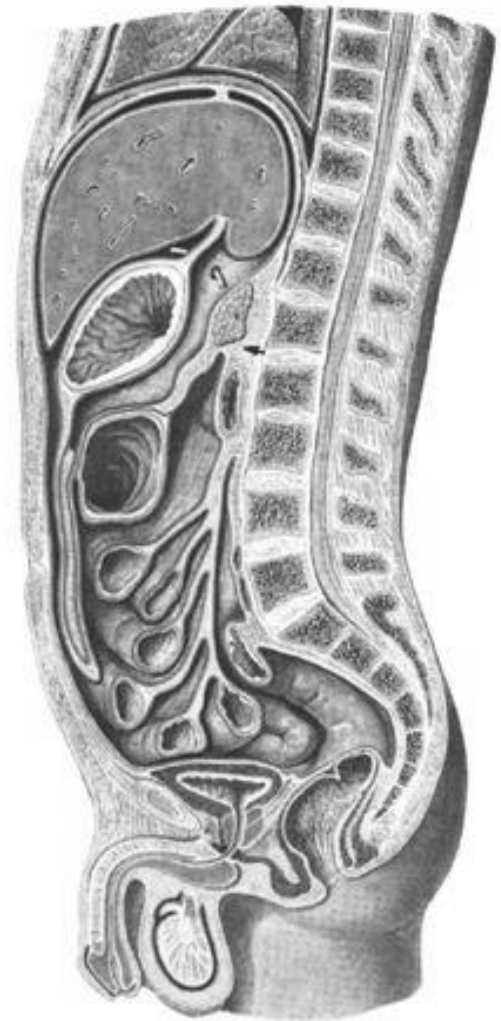1. Liver
2. Gall bladder
3. Stomach
4. Spleen
5. Pancreas
6. Duodenum (proximal part)
7. Duodenum (major part)
8. Duodenum (distal part)
9. Jejunum
10. Ileum
11. Caecum
12. Vermiform appendix
13. Ascending colon
14. Transverse colon
15. Descending colon
16. Sigmoid colon
17. Rectum (upper part)
18. Rectum (middle part)
19. Rectum (lower part)
20. Kidneys
21. Suprarenal glands
22. Urinary bladder (full)
23. Urinary bladder (empty)
24. Ureter
25. Uterus
26. Uterine tubes
27. Ovaries
28. Prostate
29. Deferent ducts
30. Seminal vesicles

[illegible]

Task 31: Mark with colored lines the bursae of the upper storey of the peritoneal cavity and the epiploic foramen.

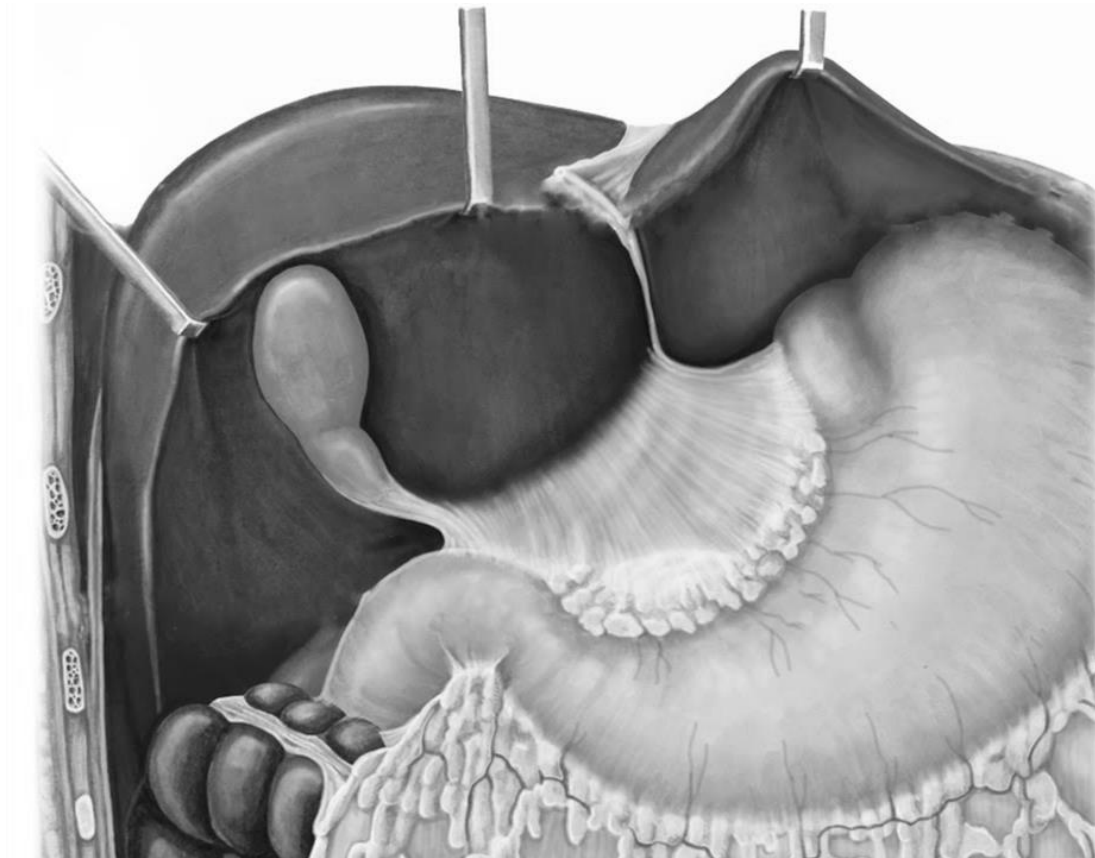


**Organs of peritoneal cavity
(anterior aspect)**



**Organs of abdominal
cavity
(sagittal aspect)**

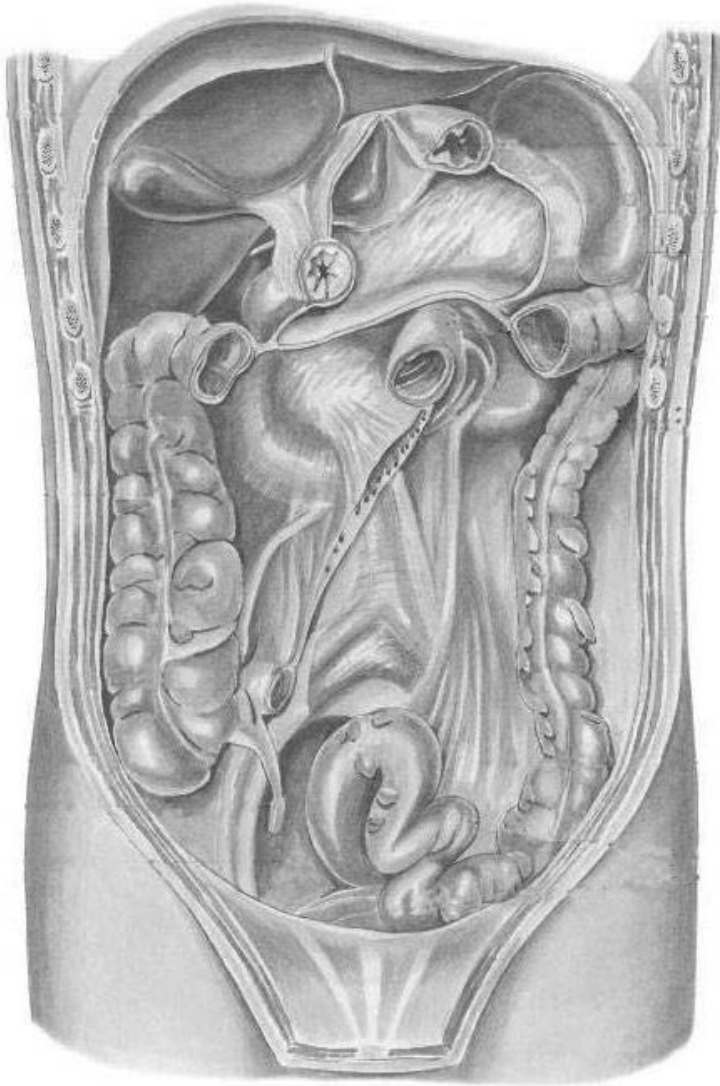
Task 32: Indicate the listed structures on the following picture. Indicate and write the components of the lesser omentum.



1. Hepatic bursa (bursa hepatica)
2. Pregastric bursa (bursa pregastrica)
3. Epiploic foramen (foramen epiploicum)
4. Lesser omentum (omentum minus)
5. Greater omentum (omentum majus)

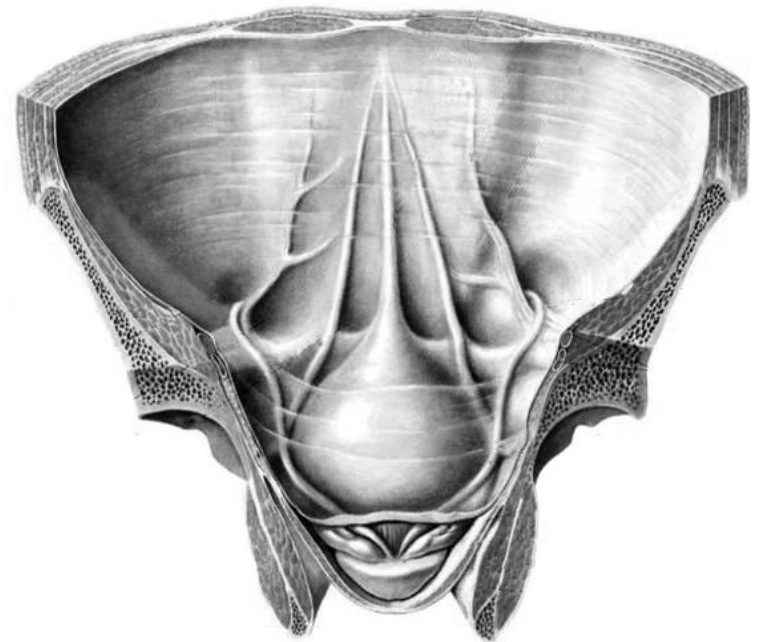
**Organs of upper storey
of peritoneal cavity
(anterior aspect)**

Task 33: Indicate the listed structures on the following pictures.



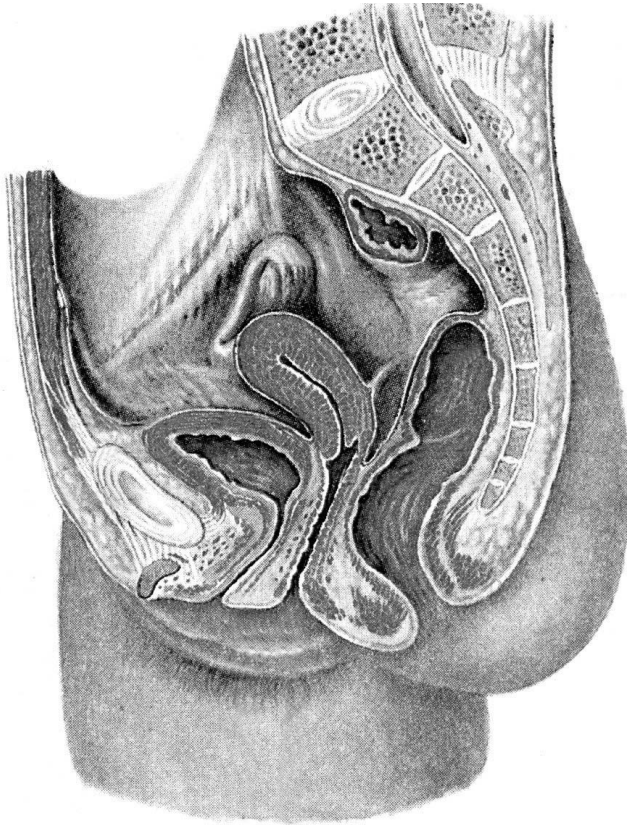
**Posterior wall
of peritoneal cavity
(anterior aspect)**

1. Root of transverse mesocolon (mesocolon transversus)
2. Mesenteric root of the small intestine
3. Right mesenteric sinus (sinus mesentericus dexter)
4. Left mesenteric sinus (sinus mesentericus sinister)
5. Right paracolic groove (sulcus paracolicus dexter)
6. Left paracolic groove (sulcus paracolicus sinister)
7. Superior duodenal recess (recessus duodenalis superior)
8. Inferior duodenal recess (recessus duodenalis inferior)
9. Superior ileocaecal recess (recessus ileocaecalis superior)
10. Inferior ileocaecal recess (recessus ileocaecalis inferior)
11. Mesoappendix
(mesoappendix)
12. Sigmoid mesocolon
(mesocolon sigmoideum)
13. Median umbilical fold
(plica umbilicalis mediana)
14. Medial umbilical fold
(plica umbilicalis medialis)
15. Lateral umbilical fold
(plica umbilicalis lateralis)
16. Supravesical fossa (fossa
supravesicalis)
17. Medial inguinal fossa
(fossa inguinalis medialis)
18. Lateral inguinal fossa
(fossa inguinalis lateralis)

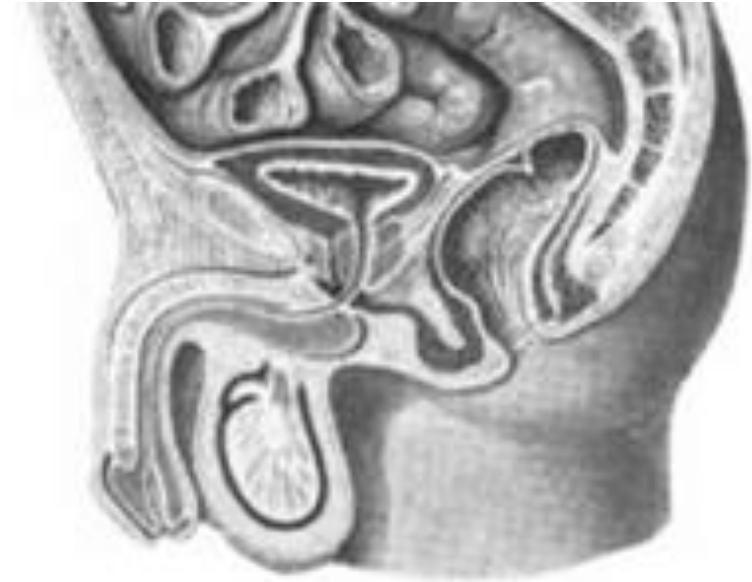


**Inner surface of anterior
abdominal wall
(anterior aspect)**

Task 34: Mark with colored lines the pouches of the female and male pelvis, and write their names.



**Organs of female pelvis
(sagittal aspect)**



**Organs of male pelvis
(sagittal aspect)**

