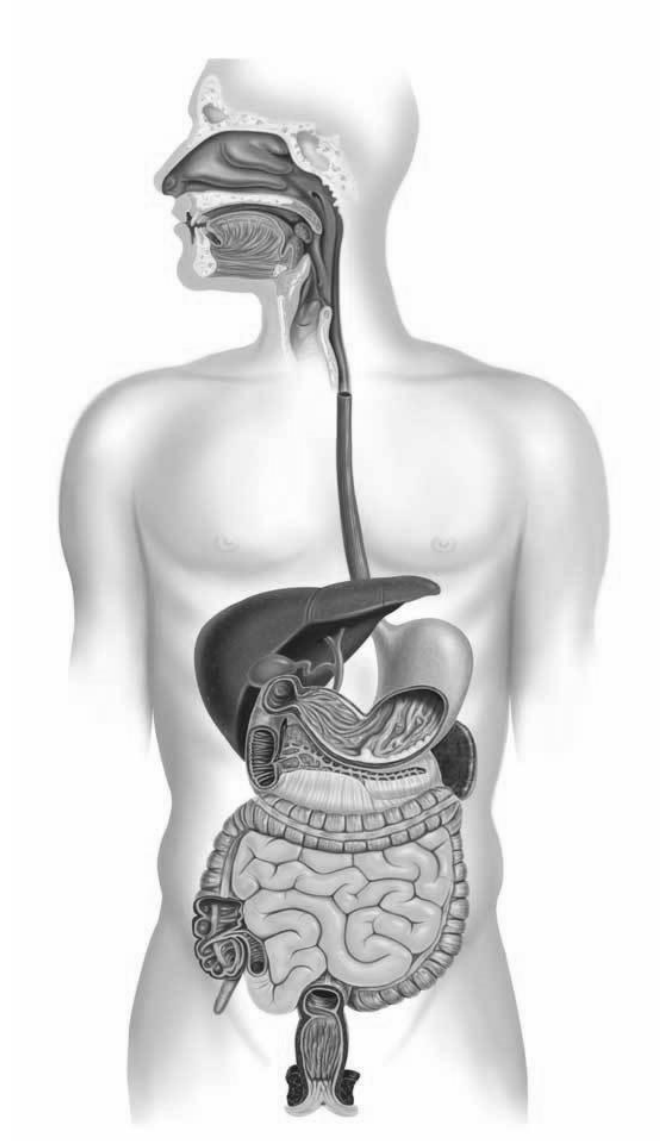
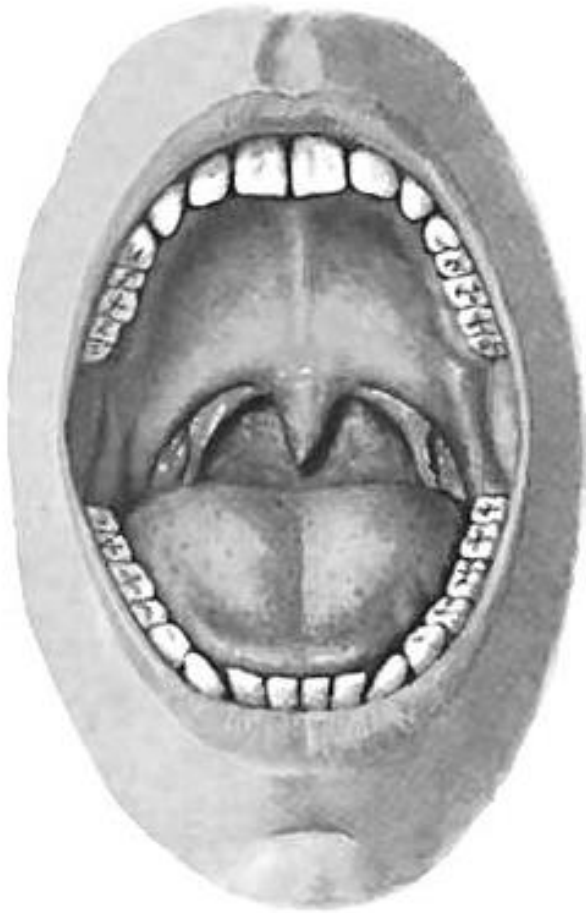


Task 1: Indicate and write in order (beginning from the oral cavity) the organs of the alimentary system on the following picture.



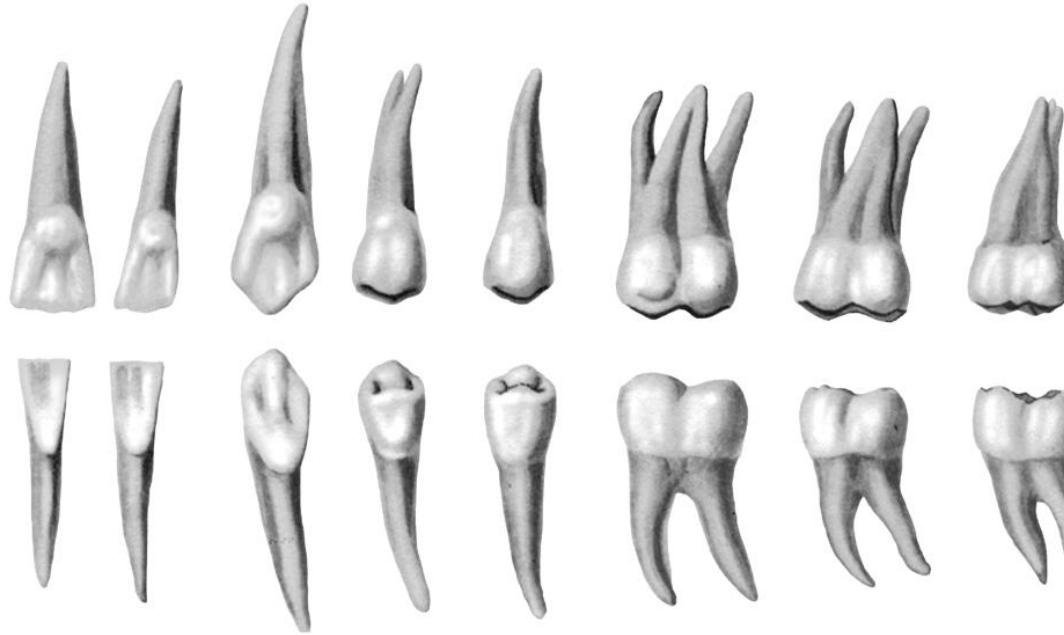Task 2: Indicate the listed structures on the following picture.



**Oral cavity
(frontal aspect)**

1. Hard palate (palatum durum)
2. Soft palate (palatum molle)
3. Palatoglossal arch (arcus palatoglossus)
4. Palatopharyngeal arch (arcus palatopharyngeus)
5. Tonsillar fossa (fossa tonsillaris)
6. Palatine tonsil (tonsilla palatina)
7. Fauces (fauces)
8. Oral vestibule (vestibulum oris)
9. Oral cavity proper (cavitas oris proprium)
10. Apex of tongue (apex linguae)
11. Body of tongue (corpus linguae)
12. Median sulcus of the tongue (sulcus medianus)
13. Uvula (uvula)
14. Incisor teeth (dentes incisivi)
15. Canine teeth (dentes canini)
16. Premolar teeth (dentes premolares)
17. Molar teeth (dentes molares)

Task 3: Write the types of teeth on the following picture. Indicate the parts of teeth.

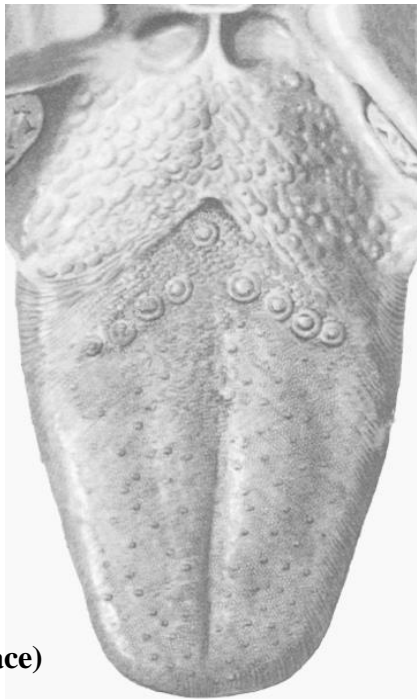

Task 4: Write the dental formulae.

	Anatomical formula		Clinical formula	
	Right quadrant	Left quadrant	Right quadrant	Left quadrant
1) Formula of milk teeth	<hr/>	<hr/>	<hr/>	<hr/>
2) Formula of permanent teeth	<hr/>	<hr/>	<hr/>	<hr/>

**Task 5: Indicate the listed structures
on the following picture.**

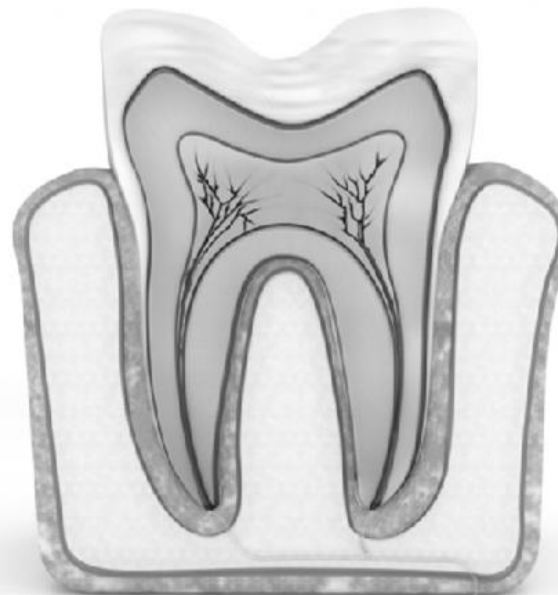1. Root of tongue (radix linguae)
2. Apex of tongue (apex linguae)
3. Body of tongue (corpus linguae)
4. Terminal sulcus (sulcus terminalis)
5. Median sulcus of the tongue (sulcus medianus)
6. Foramen caecum (foramen caecum)
7. Frenulum of tongue (frenulum linguae)
8. Filiform papillae (papillae filiformes)
9. Fungiform papillae (papillae fungiformes)
10. Vallate papillae (papillae vallatae)
11. Foliate papillae (papillae foliatae)
12. Papillae conicae (conical papillae)
13. Lingual tonsil (tonsilla lingualis)
14. Glossoepiglottic folds (median and laterals)
15. Epiglottic valleculae (valleculae epiglotticae)



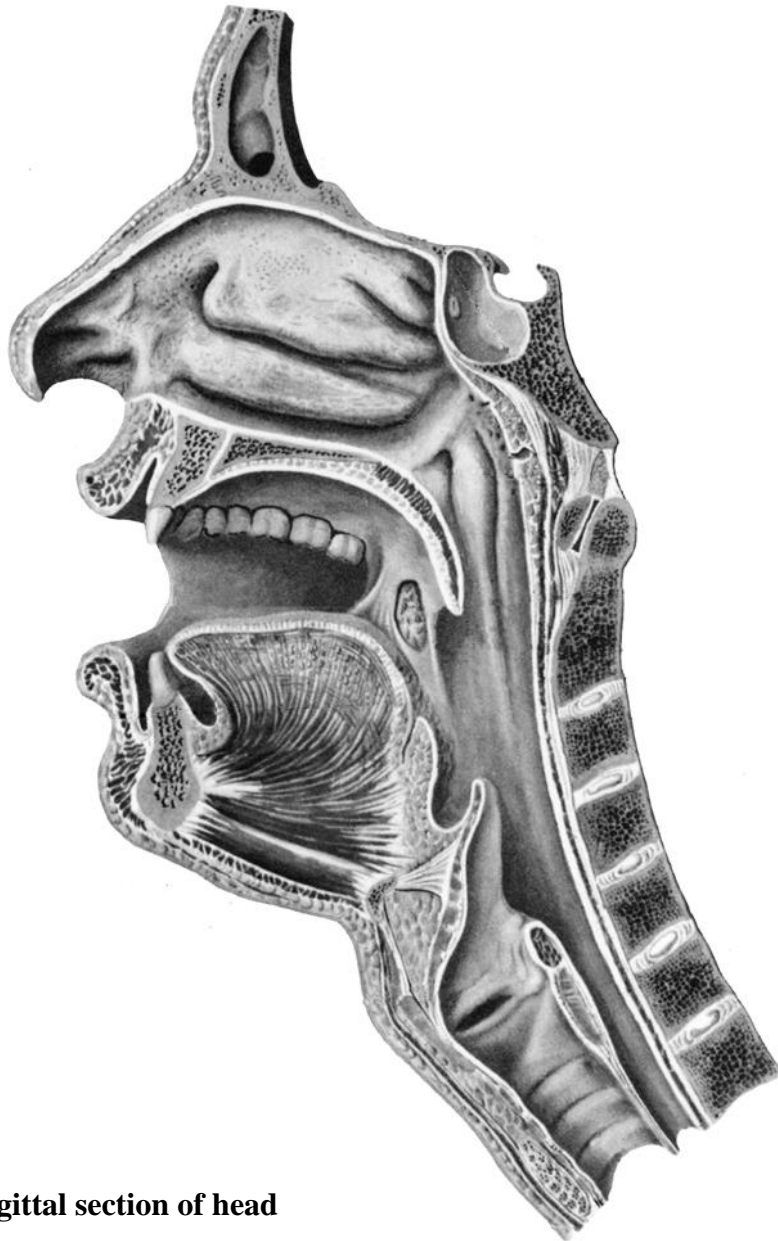**Tongue
(superior surface)**

**Task 6: Indicate the listed structures
on the following picture.**

1. Root of tooth (radix dentis)
2. Crown of tooth (corona dentis)
3. Neck of tooth (cervix dentis)
4. Incisor teeth (dentes incisivi)
5. Canine teeth (dentes canini)
6. Premolar teeth (dentes premolares)
7. Enamel (enamelum)
8. Dentin (dentinum)
9. Pulp (pulpa)
10. Pulp cavity (cavitas pulparis)
11. Apical foramen (foramen apicis dentis)
12. Root canal (canalis radialis dentis)
13. Periodontal ligament (periodontium)
14. Parodontium (parodontium)



**Tooth
(longitudinal section)**

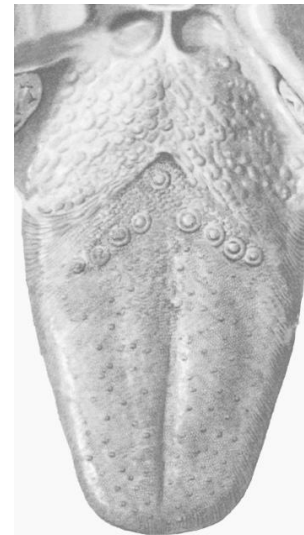

Sagittal section of head

Task 7: Indicate the listed muscles on the picture.

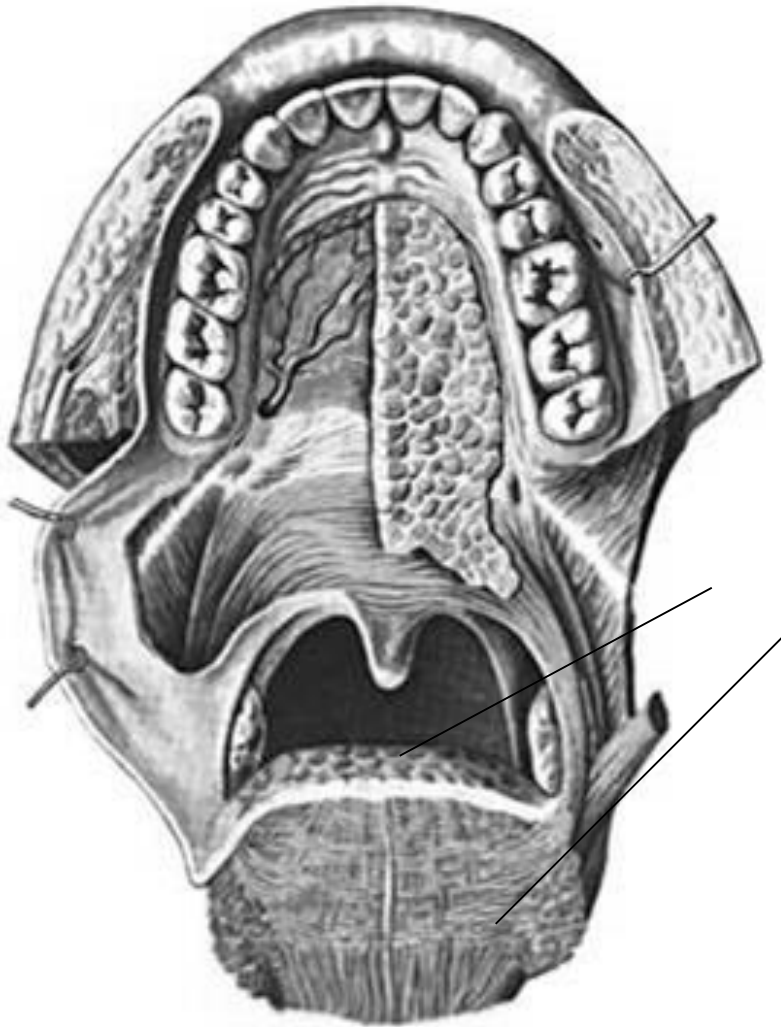
1. Mylohyoid (m. mylohyoideus)
2. Geniohyoid (m. geniohyoideus)
3. Genioglossus (m. genioglossus)
4. Superior longitudinal muscle of tongue (m. longitudinalis superior)
5. Inferior longitudinal muscle of tongue (m. longitudinalis inferior)
6. Transverse muscle of tongue (m. transversus linguae)
7. Vertical muscle of tongue (m. verticalis linguae)

Task 8: Mark with colored pencils the regions of taste on the picture (sweet, bitter, salty, sour).



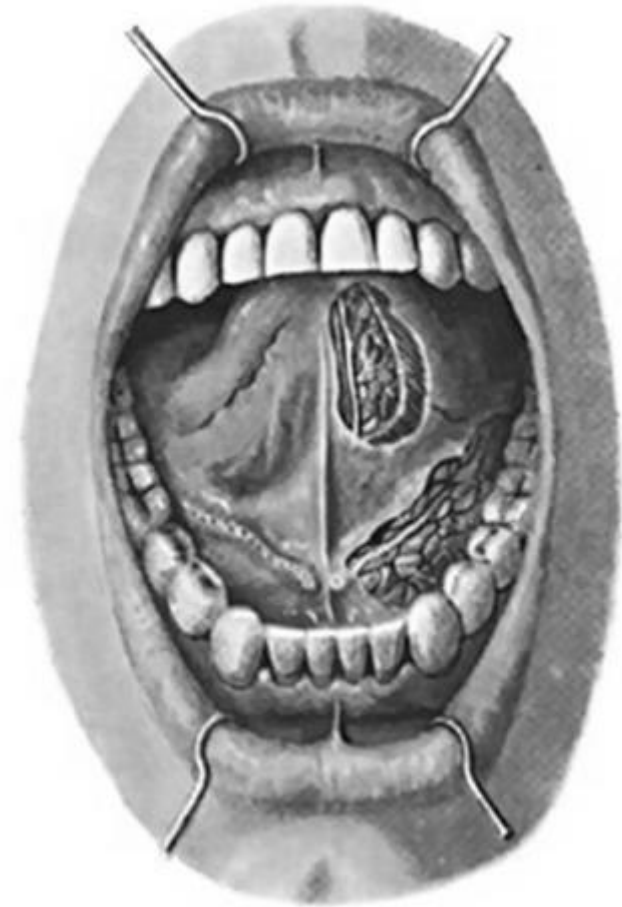**Tongue
(superior surface)**

Task 9: Indicate and write the muscles of the soft palate on the following picture.



Muscles of soft palate

Task 10: Write the names of indicated structures, and write what salivary glands open here.



**Oral cavity
(frontal aspect)**

