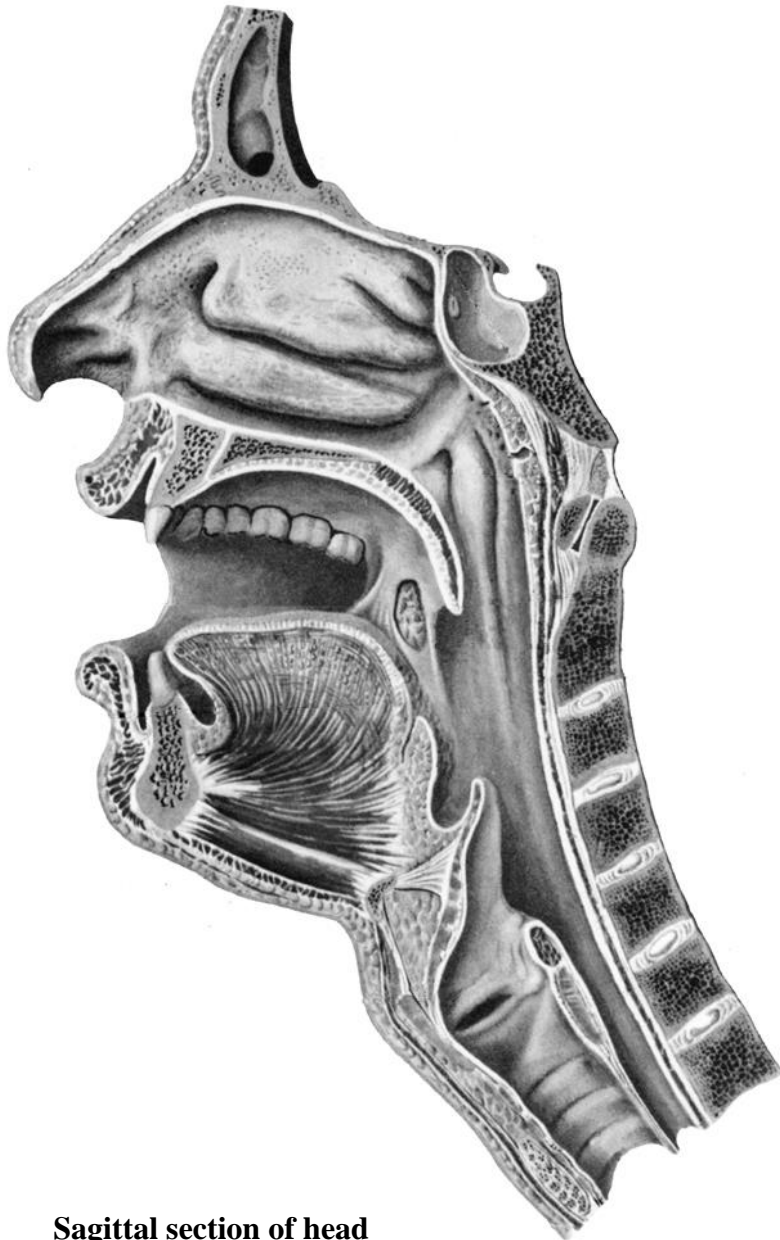


**Task 11: Mark with colored pencils
the parts of the pharynx on the picture.**

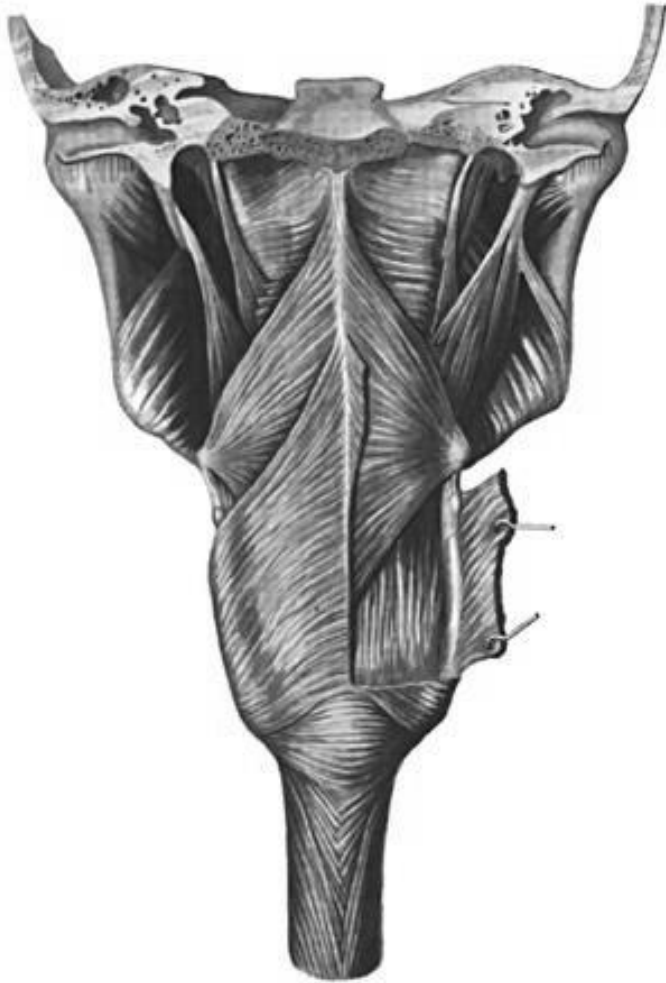


Sagittal section of head

**Task 12: Indicate the listed structures
on the picture.**

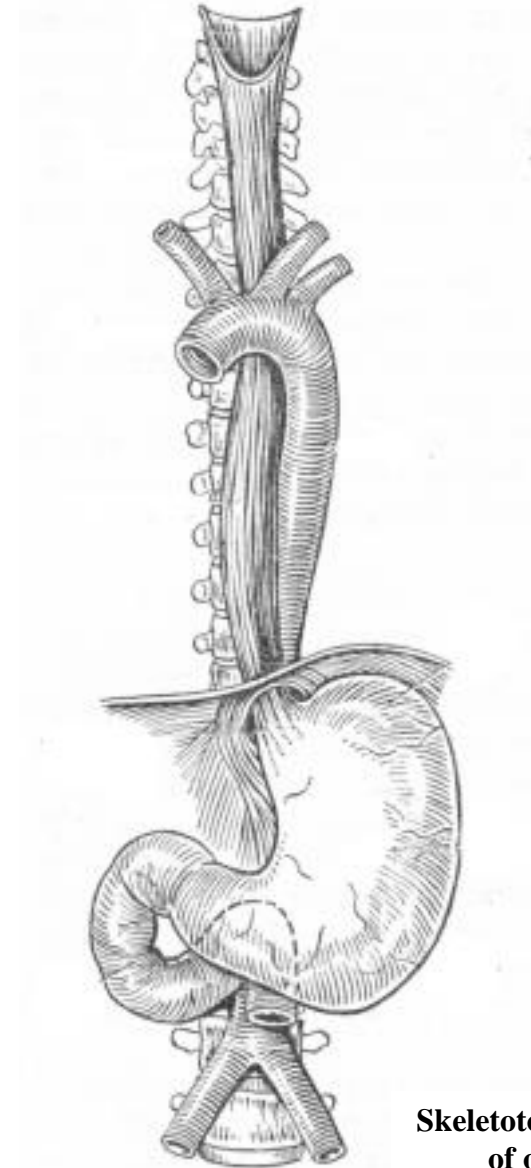
1. Hard palate (palatum durum)
2. Soft palate (paltum molle)
3. Palatoglossal arch (arcus palatoglossus)
4. Palatopharyngeal arch (arcus palatopharyngeus)
5. Tonsilar fossa (fossa tonsillaris)
6. Palatine tonsil (tonsilla palatina)
7. Fauces (fauces)
8. Oral vestibule (vestibulum oris)
9. Oral cavity proper (cavitas oris proprium)
10. Root of tongue (radix linguae)
11. Apex of tongue (apex linguae)
12. Body of tongue (corpus linguae)
13. Uvula (uvula)
14. Pharyngeal opening of the auditory tube (ostium pharyngeum tubae auditivae)
15. Torus tubarius (torus tubarius)
16. Pharyngeal fornix (fornix pharyngis)
17. Pharyngeal recess (recessus pharyngeus)
18. Salpingopharyngeal fold (plica salpingopharyngea)

Task 13: Indicate the pharyngeal muscles on the following picture, and write their names.



**Muscles of pharynx
(posterior aspect)**

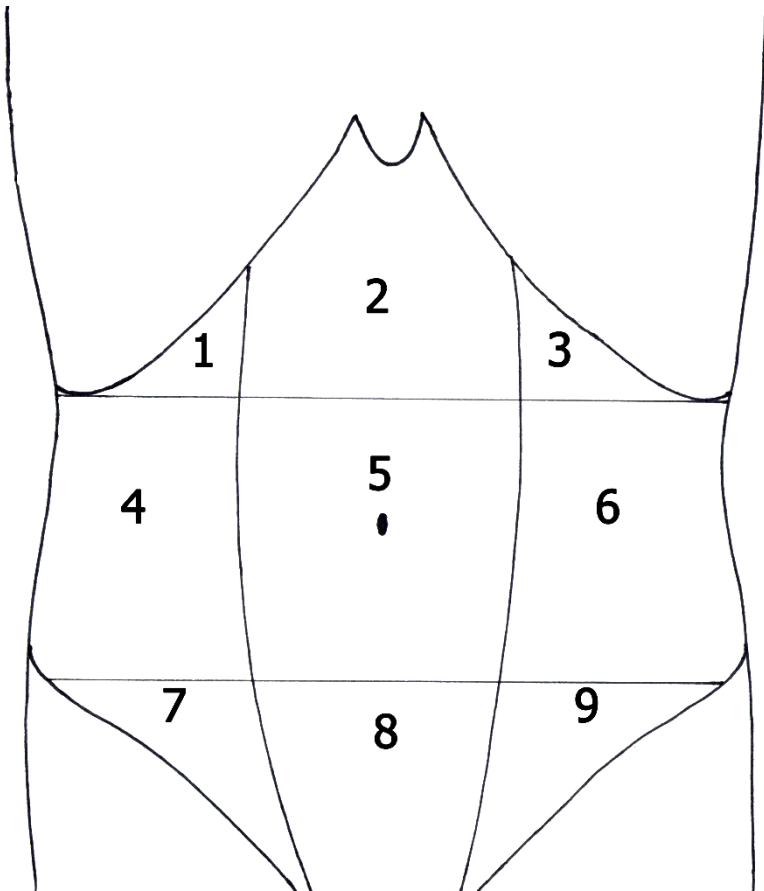
Task 14: Mark the oesophageal constrictions (anatomical and physiological) and indicate the skeletotopy of each of them on the following picture.



**Skeletotopy and syntopy
of oesophagus**

Task 15:

- a) Mark with colored pencils the regions of the anterior abdominal wall (epigastrium, mesogastrium and hypogastrium).**
- b) Write the names of the regions of the anterior abdominal wall, indicated in the picture by numbers.**
- c) Write the names of the digestive organs that project to each of these regions.**



1 _____
Organs: _____

— 2 _____
Organs: _____

3 _____
Organs: _____

4 _____
Organs: _____

5 _____
Organs: _____

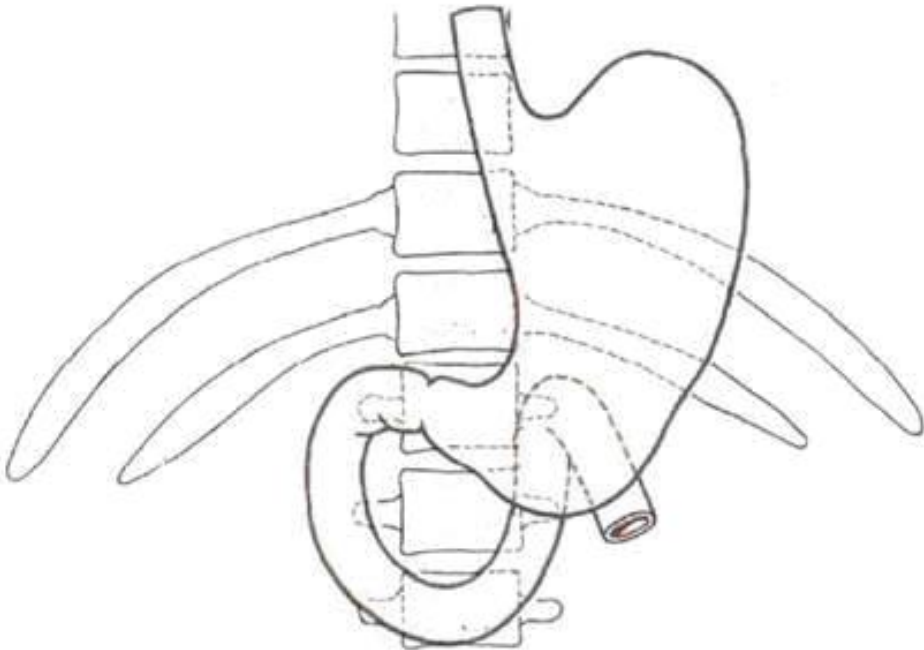
6 _____
Organs: _____

7 _____
Organs: _____

8 _____
Organs: _____

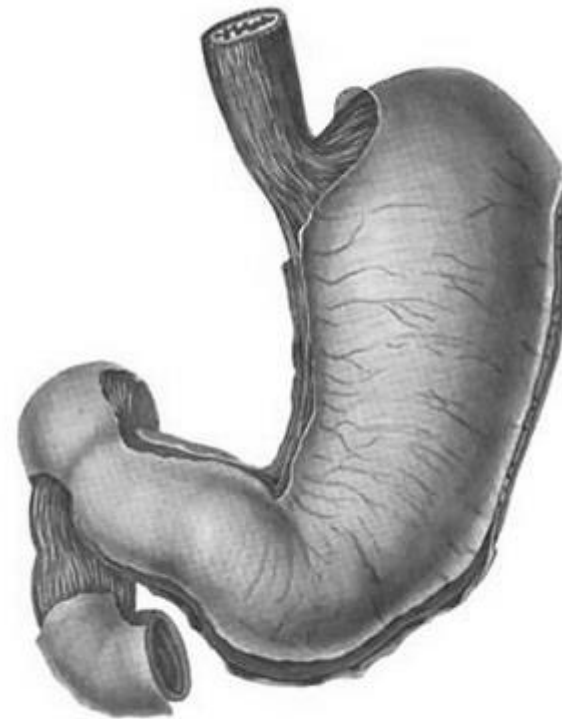
9 _____
Organs: _____

Task 16: Write the numbers of the vertebrae on the following picture to show the skeletotopy of the stomach.



Task 17: Indicate the listed structures on the following picture.

1. Anterior wall of stomach (paries anterior)
2. Posterior wall of stomach (paries posterior)
3. Lesser curvature (curvatura minor)
4. Greater curvature (curvatura major)
5. Pyloric part (pars pylorica)
6. Pyloric antrum (antrum pyloricum)
7. Pyloric canal (canalis pyloricus)
8. Pyloric sphincter (musculus sphincter pyloricus)
9. Fundus of stomach (fundus gastricus)
10. Body of stomach (corpus gastricus)
11. Cardiac part (pars cardiaca)



12. Cardiac sphincter (sphincter)
13. Cardiac orifice (ostium cardiacum)
14. Angular notch (incisura angularis)
15. Cardiac notch (incisura cardiaca)
16. Ampulla (bulb) of the duodenum (ampulla duodeni)
17. Superior, descending, horizontal and ascending parts of the duodenum

Task 18: Determine the shape of the stomachs, shown by the following radiographs (shape of horn, hook or elongated hook).

