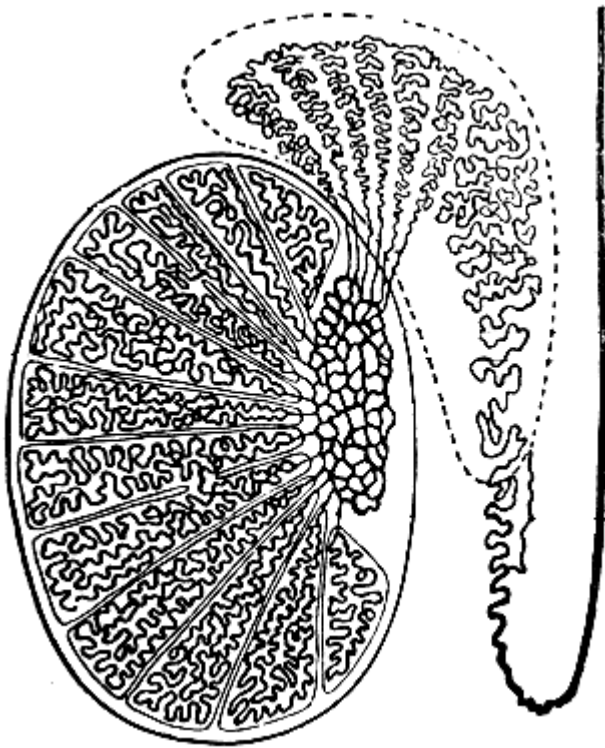


1: Indicate on the picture the following tubules and ducts of the testis to describe the excretory way of sperm.

Convolutated seminiferous tubules → straight seminiferous tubules

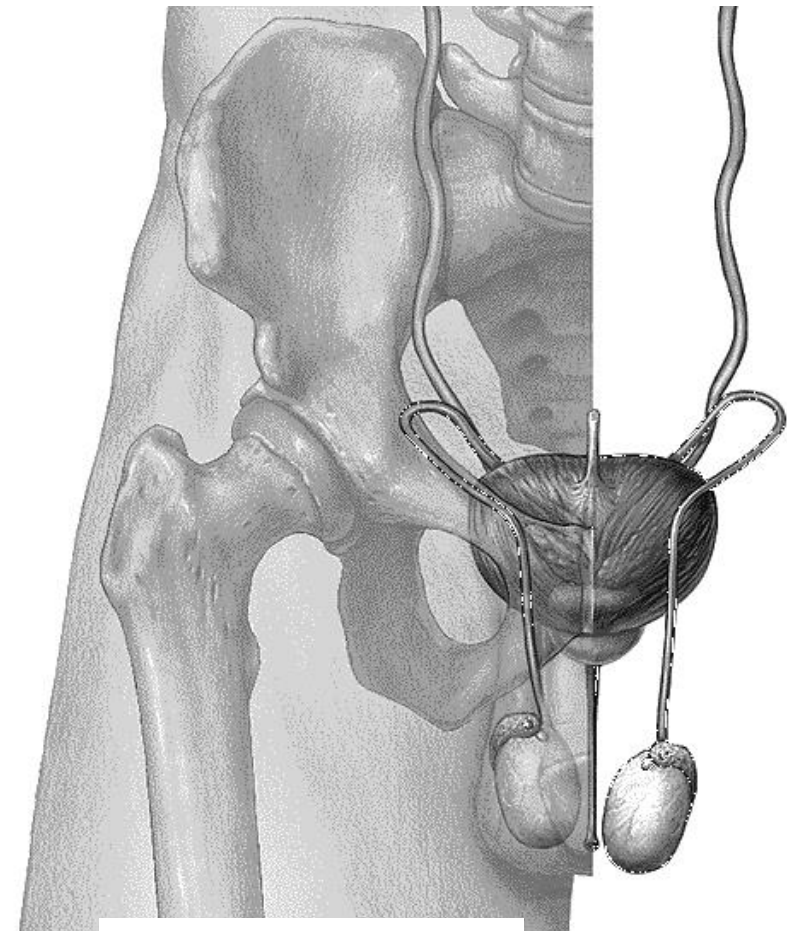
→ rete testis → efferent ductules → duct of epididymis

→ deferent duct



Testis
(longitudinal section)

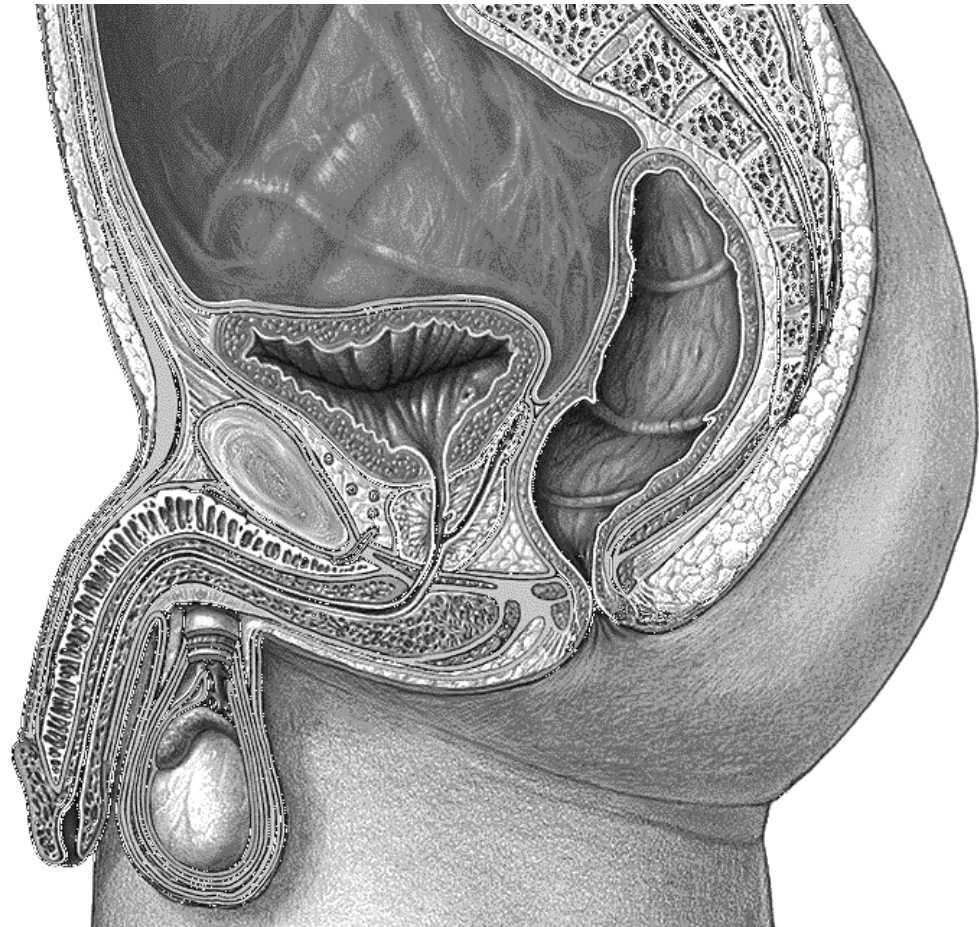
2: Indicate the parts of the deferent duct on the following picture, and write their names.



Male reproductive organs

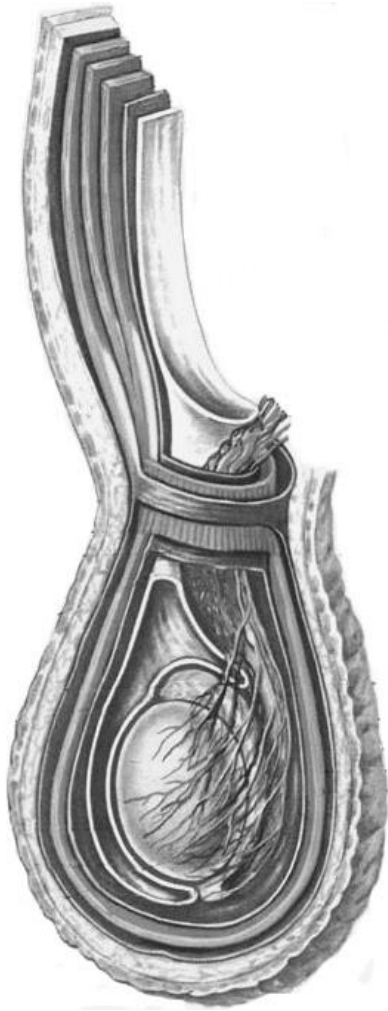
3: Indicate the listed structures on the following picture.

1. Scrotum (scrotum);
2. Tunica albuginea of testis (tunica albuginea testis);
3. Lateral surface of testis (facies lateralis testis);
4. Anterior border of testis (margo anterior testis);
5. Posterior border of testis (margo posterior testis);
6. Inferior pole of testis (extremitas inferior testis);
7. Superior pole of testis (extremitas superior testis);
8. Spermatic cord (funiculus spermaticus);
9. Epididymis (epididymis);
10. Seminal vesicles (vesiculae seminales);
11. Glans penis (glans penis);
12. Corona of glans (corona glandis);
13. Neck of glans (collum glandis);
14. Root of penis (radix penis);
15. Dorsum of penis (dorsum penis);
16. Body of penis (corpus penis);
17. Corpus cavernosum (corpora cavernosa);
18. Corpus spongiosum (corpus spongiosum);
19. Bulb of penis (bulbus penis);
20. Prostatic part of urethra (pars prostatica urethrae);
21. Membranous part of urethra (pars membranacea urethrae);
22. Spongiose part of urethra (pars spongiosa urethrae);
23. Navicular fossa (fossa navicularis);
24. Fundus of urinary bladder (fundus vesicae);
25. Body of urinary bladder (corpus vesicae);
26. Apex of urinary bladder (apex vesicae);
27. Neck of urinary bladder (cervix vesicae);
28. Ureters (ureter);
29. Internal urethral orifice (ostium urethrae internum);
30. External orifice of male urethra (ostium externum urethrae masculinum);



**Male pelvis and
reproductive organs
(sagittal section)**

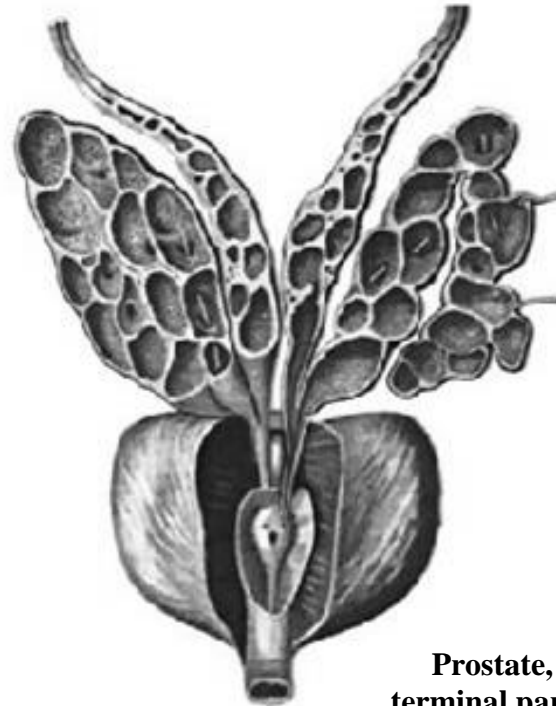4: Indicate the coverings of testis and the layers of the anterior abdominal wall, which transform into the testicular coverings, and write their names.



Coverings of testis

5: Indicate the listed structures on the following picture.

1. Deferent duct (ductus deferens);
2. Ampulla of deferent duct (ampulla ductus deferentis);
3. Seminal vesicles (vesiculae seminales);
4. Duct of seminal vesicle (ductus vesiculae seminalis);
5. Ejaculatory duct (ductus ejaculatorius);
6. Prostate (prostate): apex, base, right and left lobes;
7. Urethral crest (crista urethralis);
8. Seminal colliculus (colliculus seminalis);
9. Prostatic utricle (utricle prostaticus);
10. Prostatic sinuses (sinus prostaticus)



Prostate, seminal vesicles, terminal parts of deferent ducts (anterior aspect). Prostatic part of urethra has been dissected.