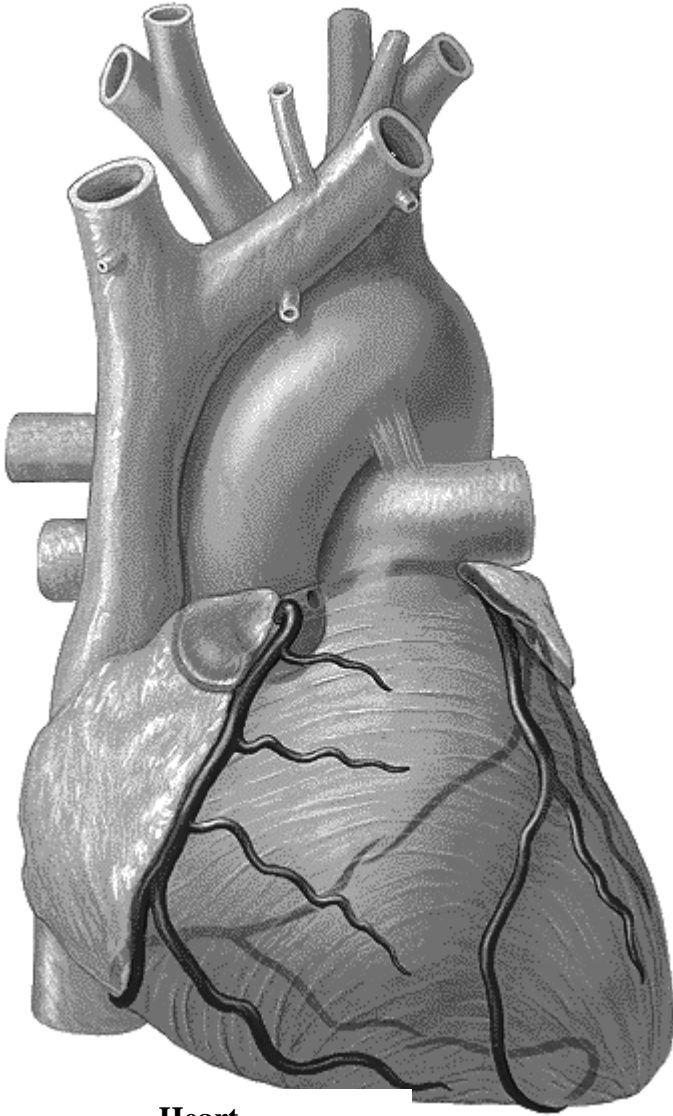
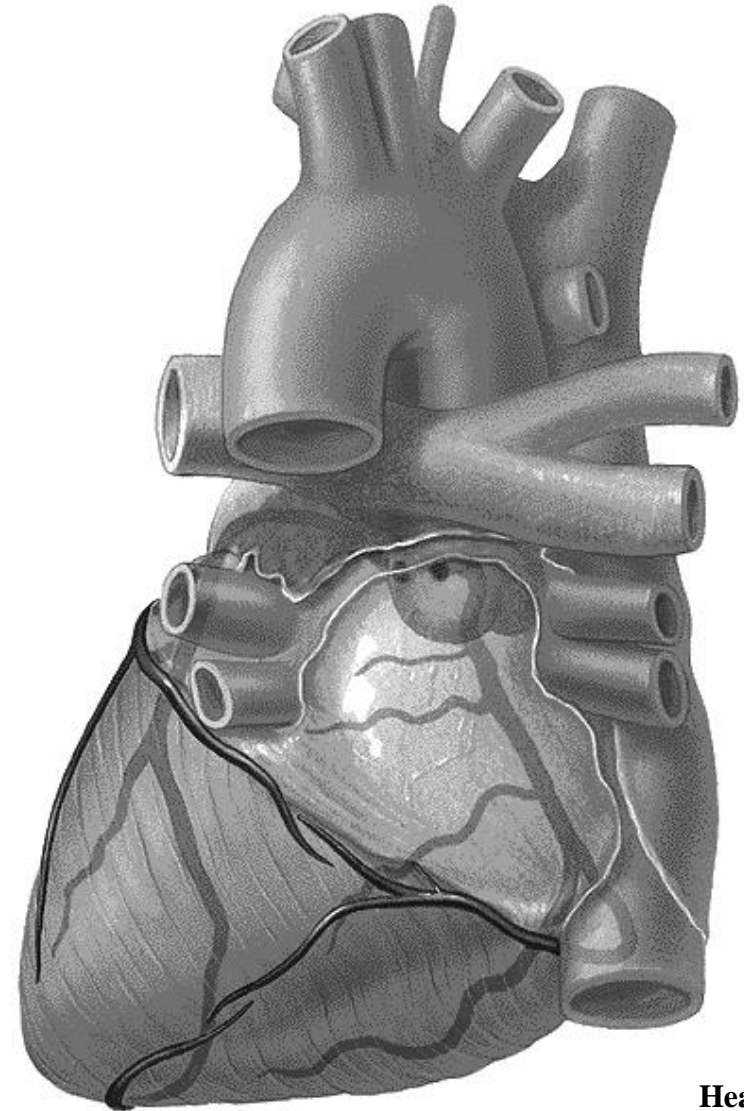


Task 1: Indicate the arteries of the heart on the following pictures, and write their names.

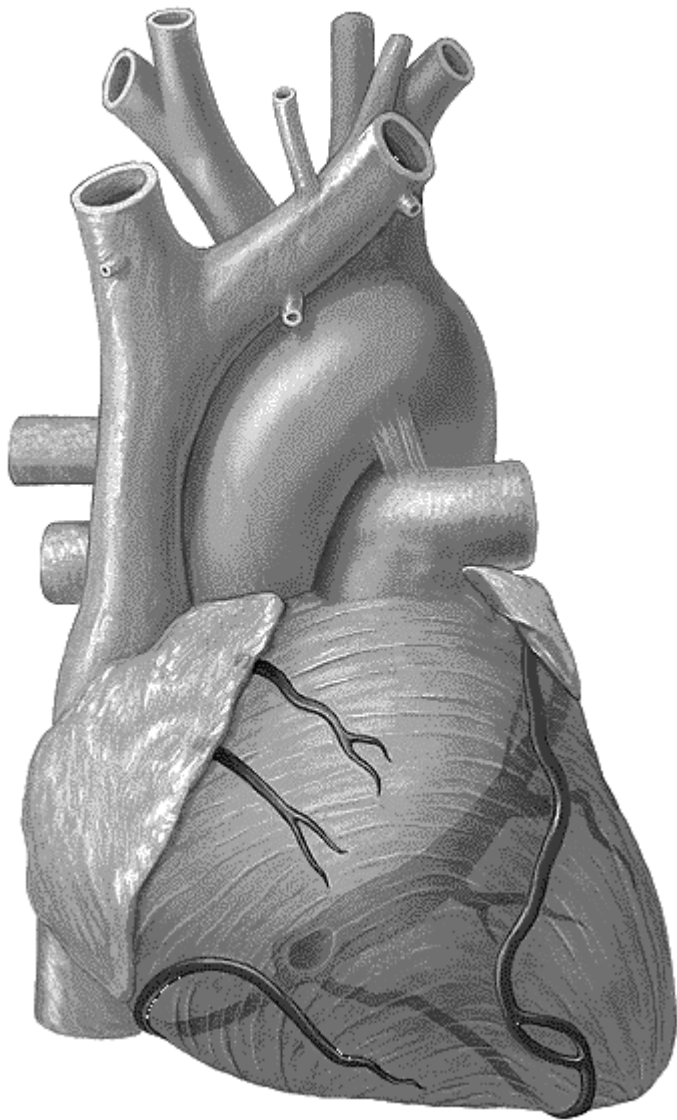


**Heart
(anterior aspect)**

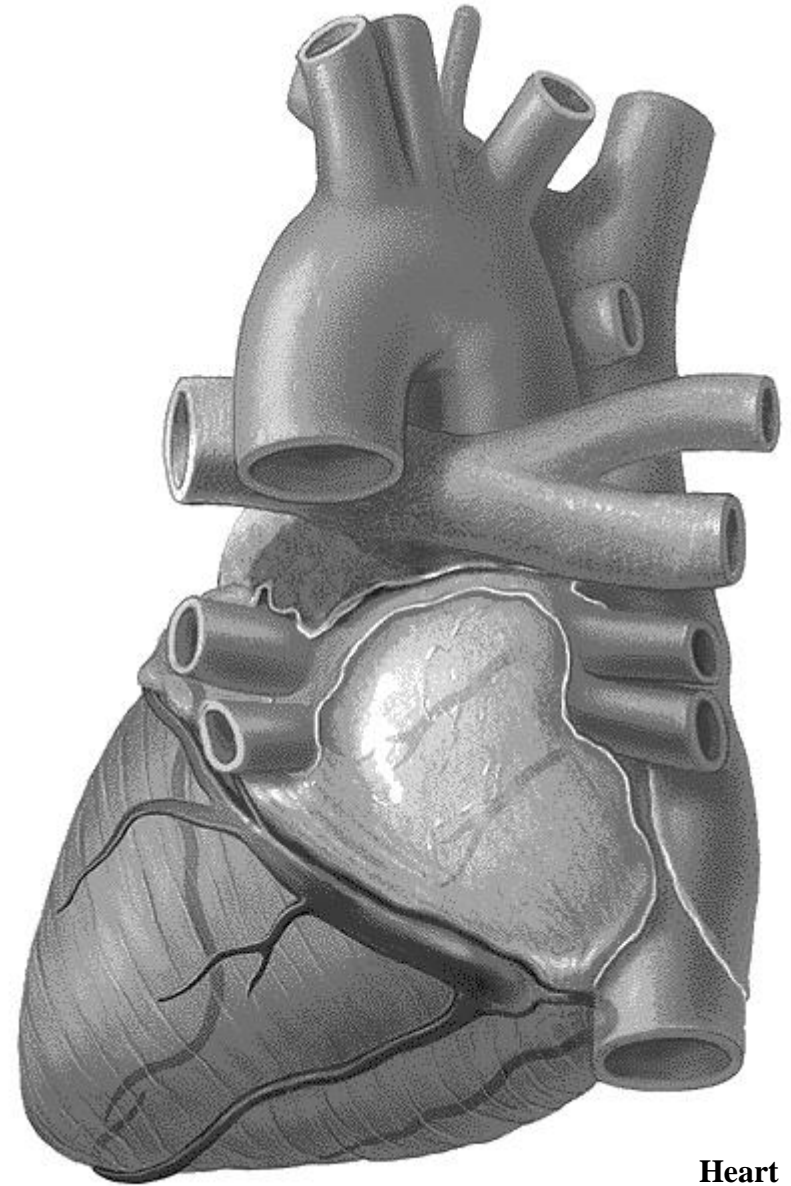


**Heart
(posterior aspect)**

Task 2: Indicate the veins of the heart on the following pictures, and write their names.



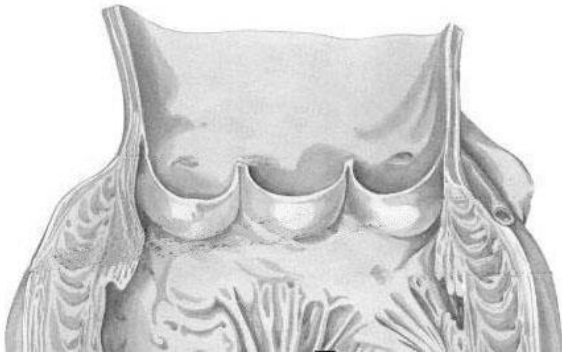
**Heart
(anterior aspect)**



**Heart
(posterior aspect)**

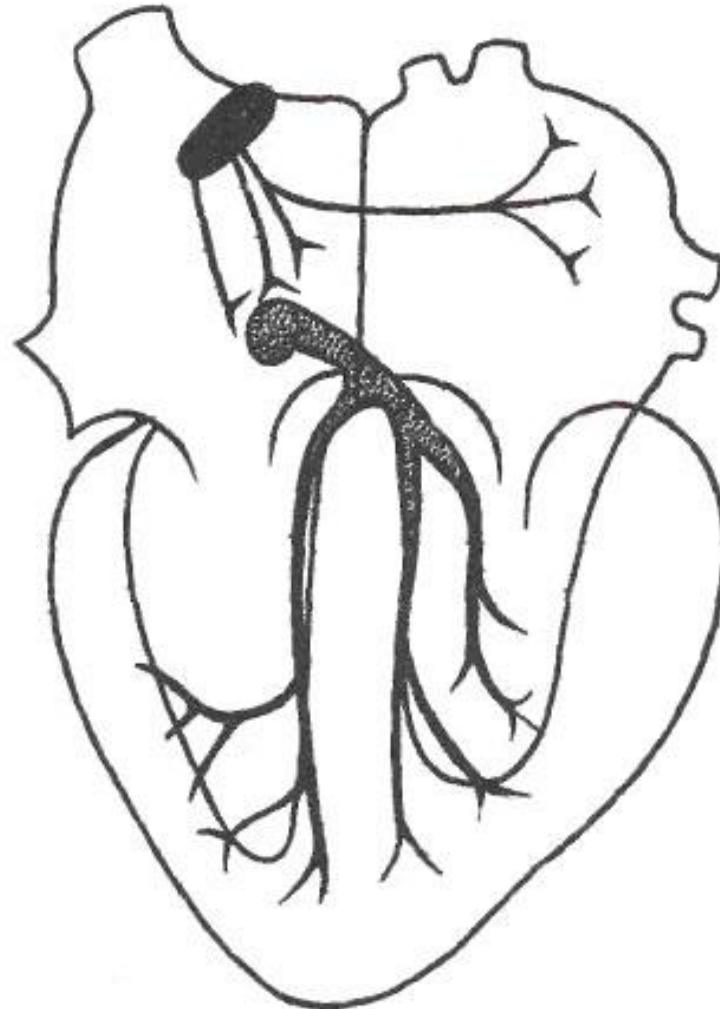
Task 3: Indicate the listed parts of the aortic valve on the following picture.

1. Aortic sinuses (sinus aortae)
2. Posterior, right and left semilunar cusps (valvula semilunaris posterior, dextra et sinistra)
3. Lunula of semilunar cusp (lunula valvulae semilunaris)
4. Nodulus of semilunar cusp (nodulus valvulae semilunaris)
5. Orifices of the coronary arteries



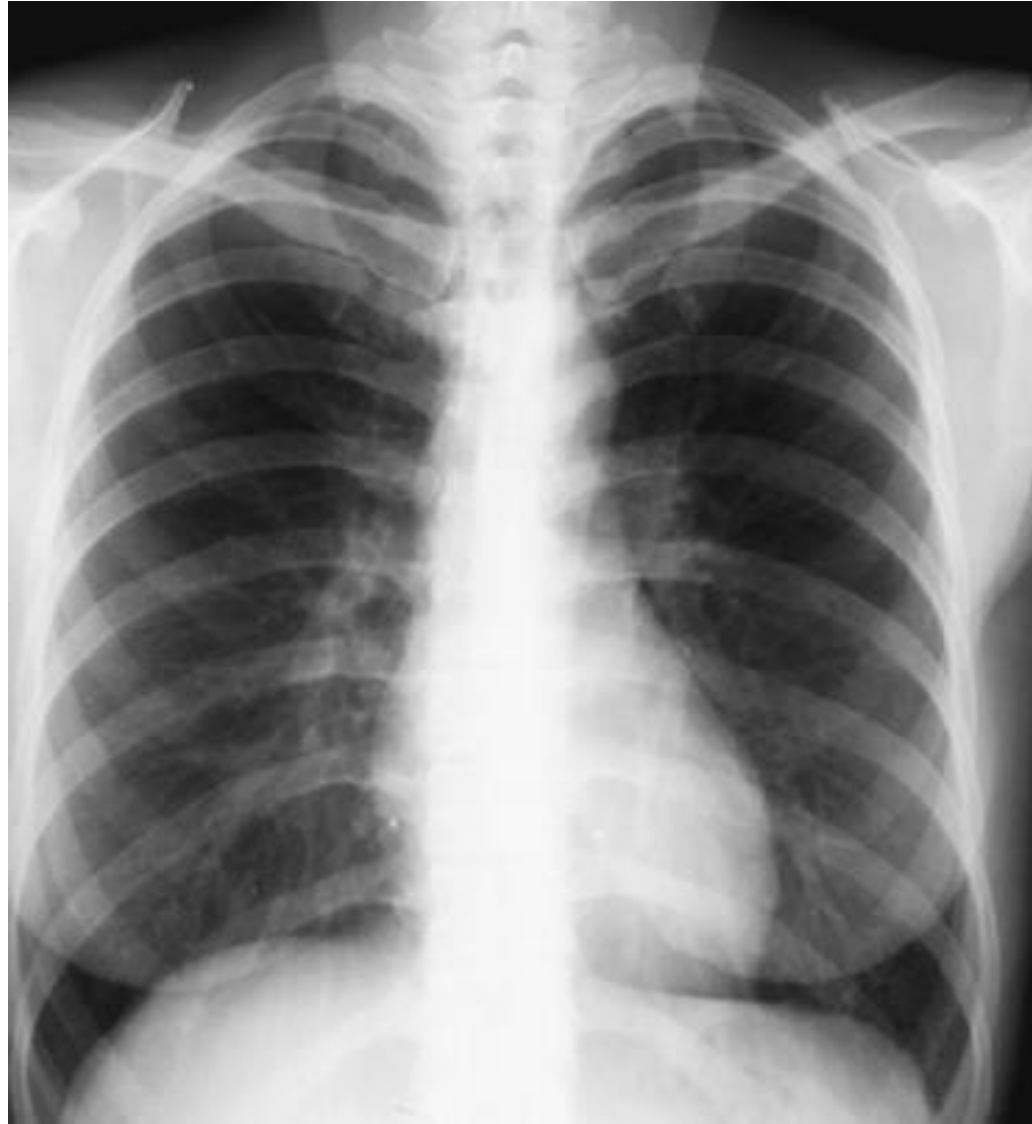Aortic valve

Task 4: Indicate and write the parts of the cardiac conducting system.



Conducting system of heart

Task 5: Mark the right and left arches of the heart, and write the names of the structures which form each of these arches.



**Radiograph of heart
(anterior aspect)**

Task 6: Write the numbers of the ribs, draw the topographical lines of thorax to show the surface projection of the cardiac borders. Write the names of the cardiac valves (they are indicated with black ovals) and write the points of their auscultation (they are indicated with circles).

