

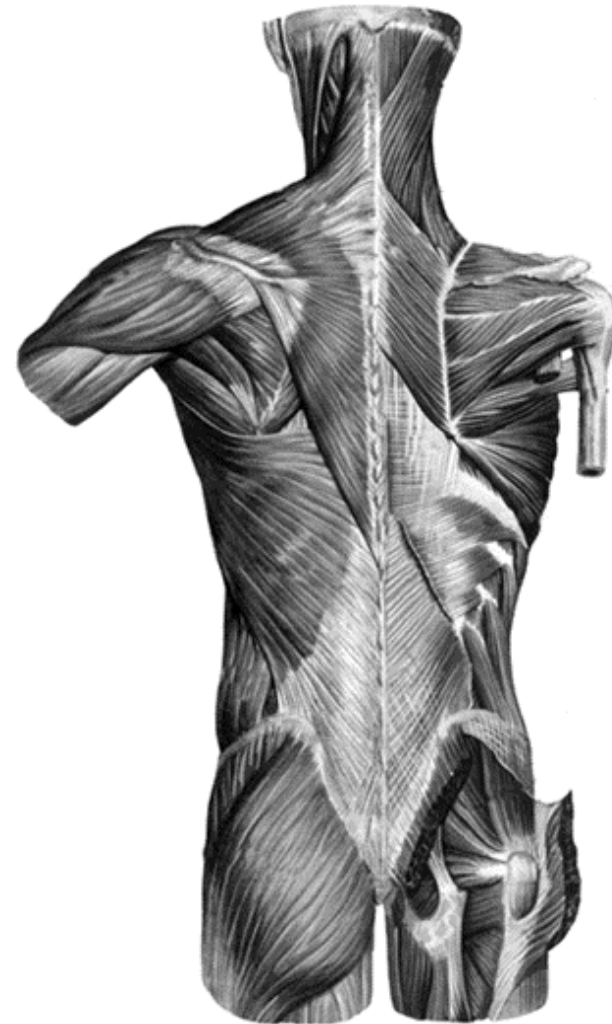SELFTESTS: THE MUSCLES AND TOPOGRAPHY OF THE BACK AND CHEST

Task 1: Indicate the listed muscles in the following picture.

1. Trapezius, *m. trapezius*;
2. Latissimus dorsi, *m. latissimus dorsi*;
3. Levator scapulae, *m. levator scapulae*;
4. Rhomboid major, *m. rhomboideus major*
5. Rhomboid minor, *et m. rhomboideus minor*;
6. Serratus posterior inferior, *m. serratus posterior inferior*;
7. Splenius capitis, *m. splenius capitis*;

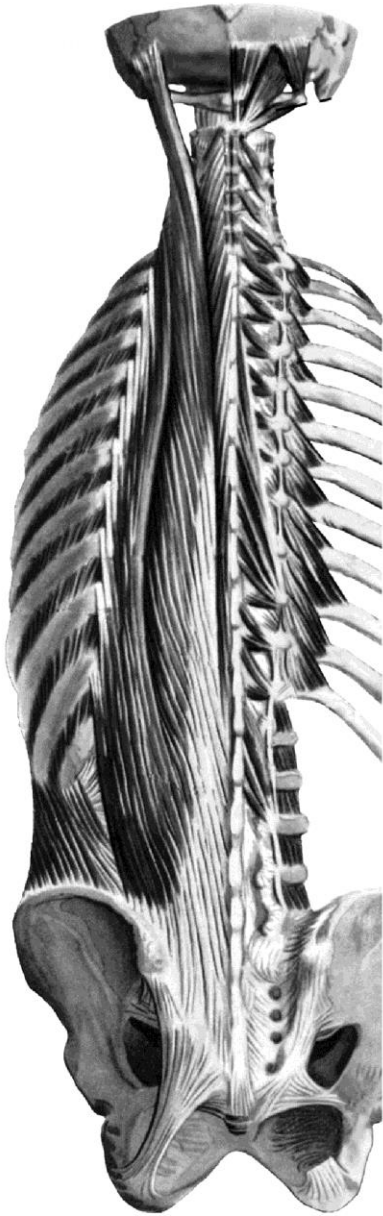**Task 2: Indicate the boundaries of the lumbar triangle with the color lines.
Write the names of all muscles, which bound it.**

Task 3: Indicate the boundaries of the lumbar rhombus with the color lines. Write the names of all the muscles, which bound it.



Task 4: Group the muscles of the back in accordance with their function, and indicate them in the picture.

1. The muscles which extend the thoracic and lumbar parts of vertebral column:
-



Deep muscles of the back

2. The muscles which extend the neck and the head

3. The muscles which rotate the vertebral column to the contralateral side

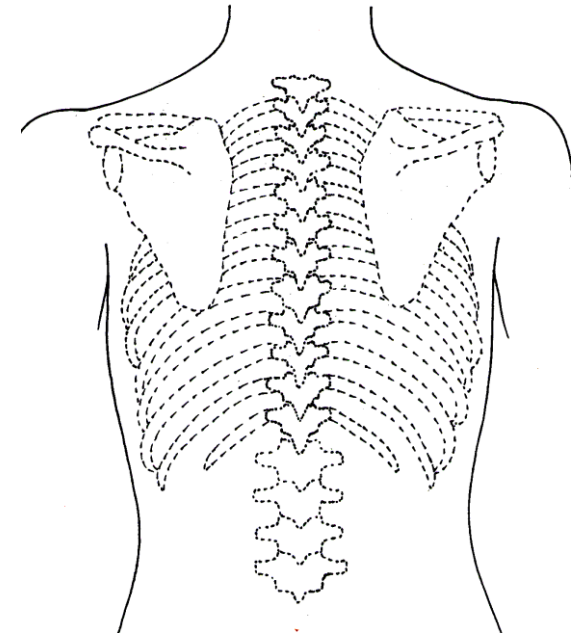
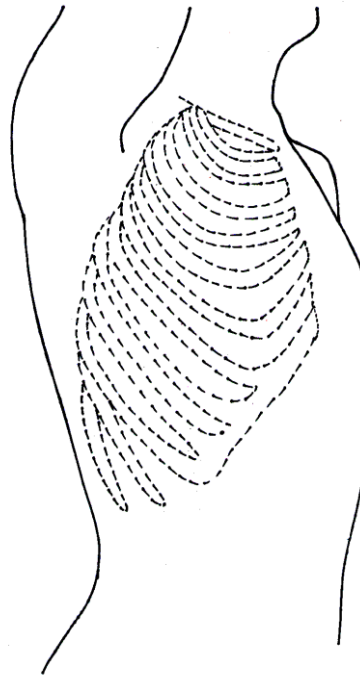
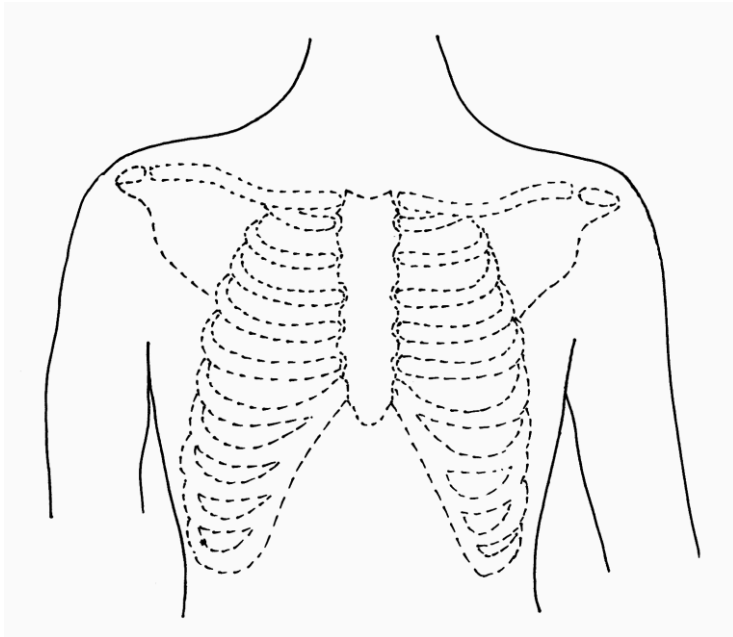
4. The muscles which elevate the ribs

5. The muscles which draw the ribs down

6. The muscles which bend the vertebral column to the sides

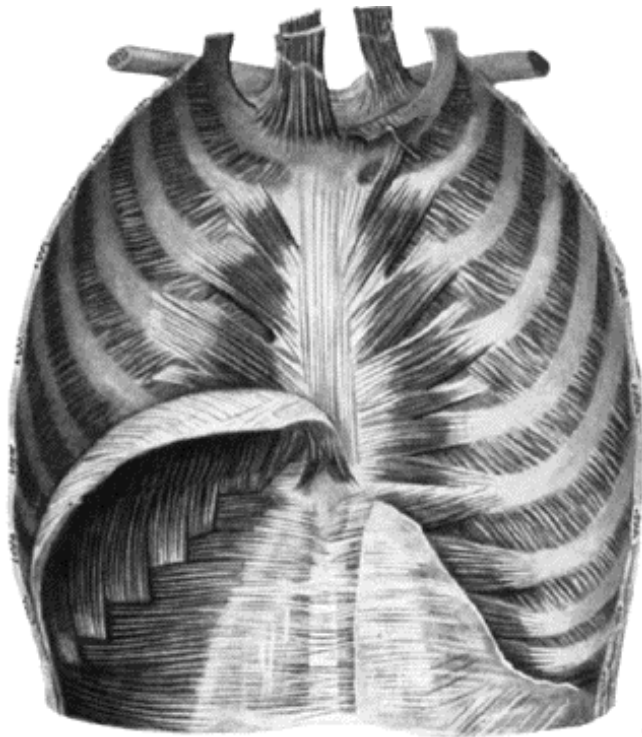
7. The muscles which bend the neck and head to the sides

Task 5: Draw the topographical lines of the thorax, and write their names.



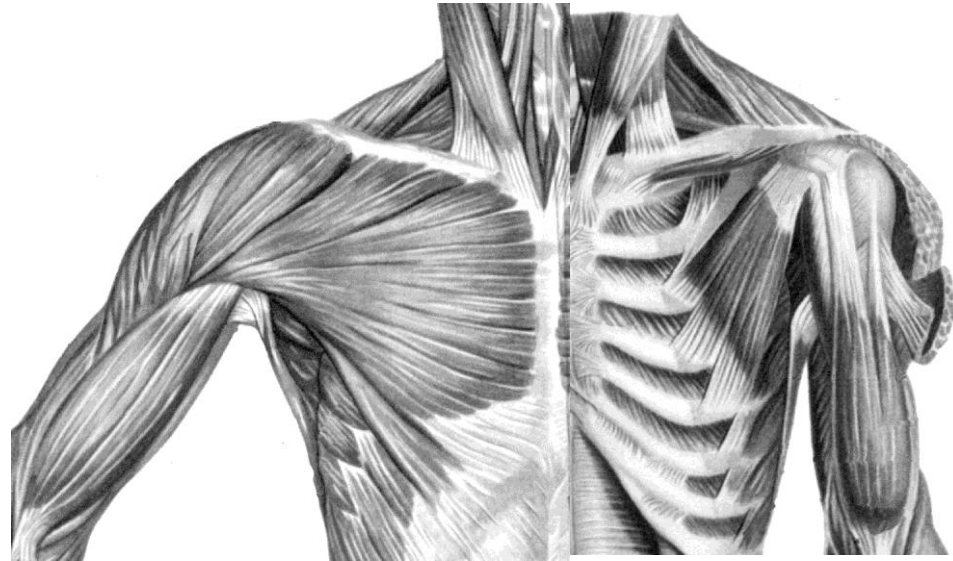
Task 6: Indicate the listed muscles in the the following picture.

1. Pectoralis major, *m. pectoralis major* ;
2. Pectoralis minor, *m. pectoralis minor*;
3. Subclavius, *m. subclavius*;
4. Serratus anterior, *m. serratus anterior*;
5. External intercostal muscles, *mm. intercostales externi*;
6. Levatores costarum, *mm. levatores costarum*;
7. Internal intercostal muscles, *mm. intercostales interni*;
8. Transversus thoracis, *m. transversus thoracis*;



**Muscles of inner surface of
chest**

(posterior aspect)



**Muscles of chest, shoulder
and arm**

(anterior aspect)

**Task 7: Indicate the boundaries
of all pectoral triangles (clavipectoral, pectoral,
subpectoral) with the color lines. Write the names
of all muscles (or bones), which bound them.**