

SELFTESTS: THE MUSCLES AND TOPOGRAPHY OF SHOULDER AND ARM

Task 1: Indicate the listed muscles in the following pictures

1. Deltoid, *m. deltoideus*;
2. Supraspinatus, *m. supraspinatus*;
3. Infraspinatus, *m. infraspinatus*;
4. Teres minor, *m. teres minor*;
5. Teres major, *m. teres major*;
6. Subscapularis, *m. subscapularis*;
7. Biceps brachii, *m. biceps brachii*;
8. Coracobrachialis, *m. coracobrachialis*;
9. Brachialis, *m. brachialis*;
10. Triceps brachii, *m. triceps brachii*;
11. Anconeus, *m. anconeus*;

Task 2: Answer the following questions:

Which of these muscles abduct the upper arm?

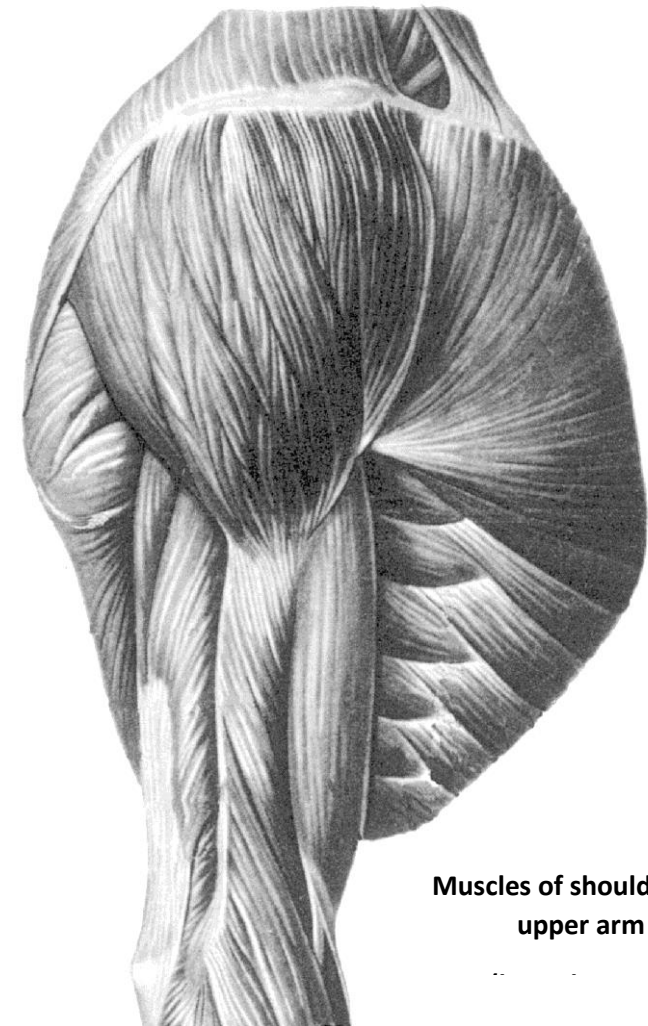
Which of these muscles adduct the upper arm?

Which of these muscles flex the upper arm?

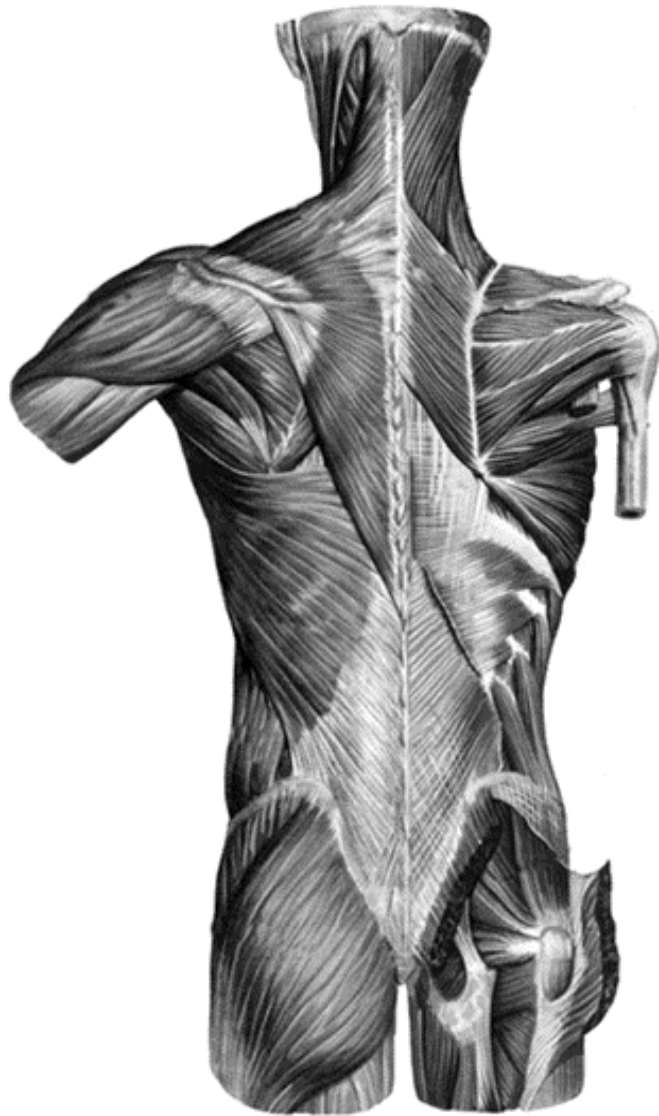Which of these muscles extend the upper arm?

Which of these muscles pronate the upper arm?

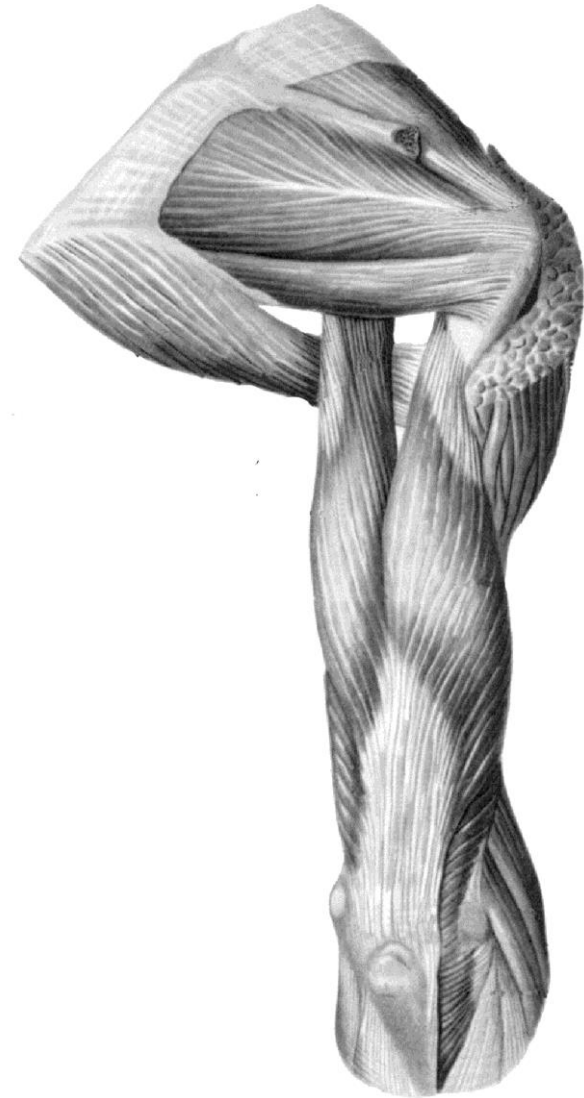
Which of these muscles supinate the upper arm?



Muscles of shoulder and
upper arm



**Superficial muscles of
back**



**Muscles of shoulder and
upper arm (posterior
aspect)**

Task 3: Write the names of the following muscles and indicate them in the picture.

1. The muscle of the anterior group of the upper arm:

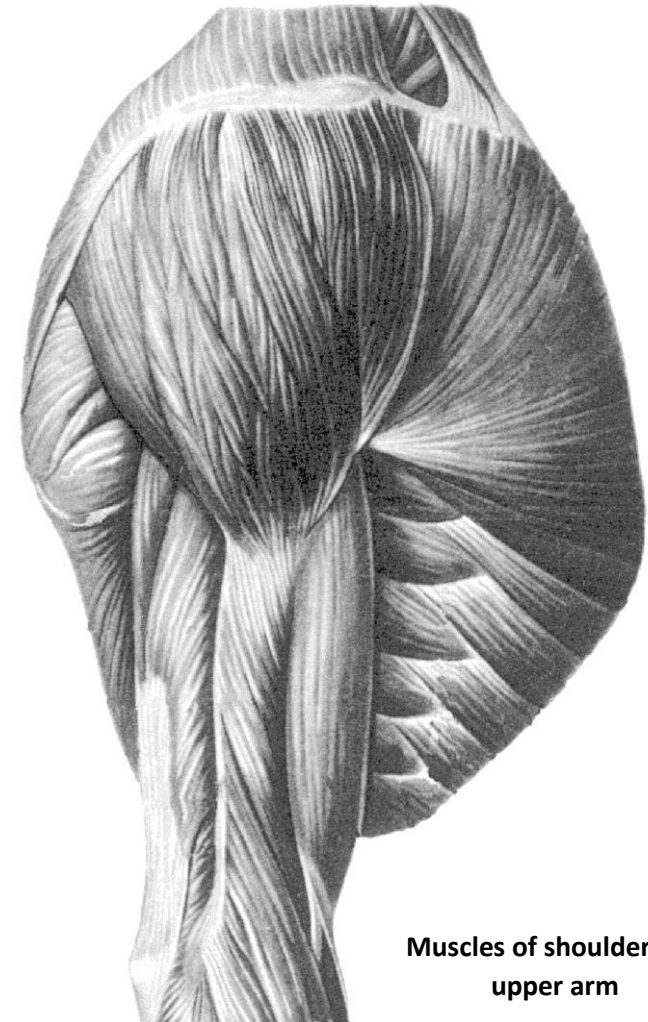
2. The muscle of the posterior group of the upper arm:

Task 4: Answer the question:

What is the general action of the anterior brachial muscles?

Task 5: Answer the question:

What is the general action of the posterior brachial muscles?



**Muscles of shoulder and
upper arm**

Task 6: Using the previous topics (the muscles of the back and chest) write the names of the muscles, acting on the shoulder joint and indicate them in the pictures.

1. The muscles which flex the upper arm: _____

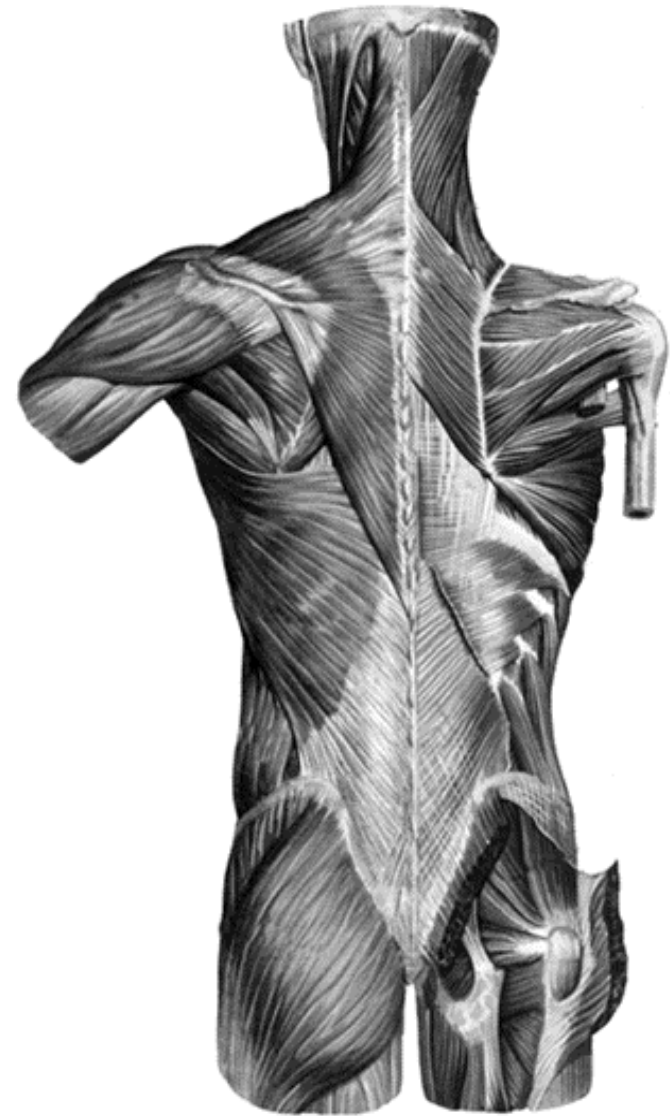
2. The muscles which extend the upper arm: _____

3. The muscles which pronate the upper arm: _____

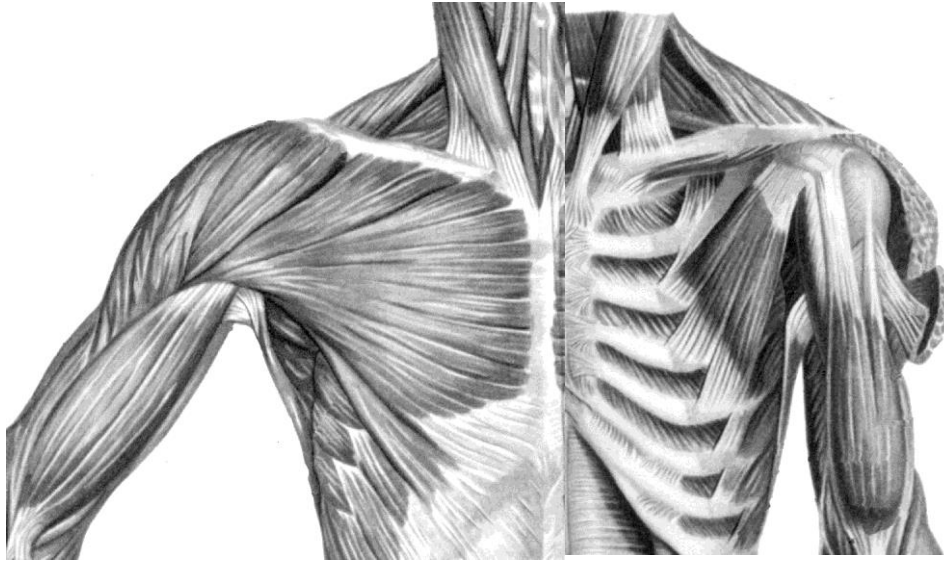
4. The muscles which supinate the upper arm: _____

5. The muscles which abduct the upper arm: _____

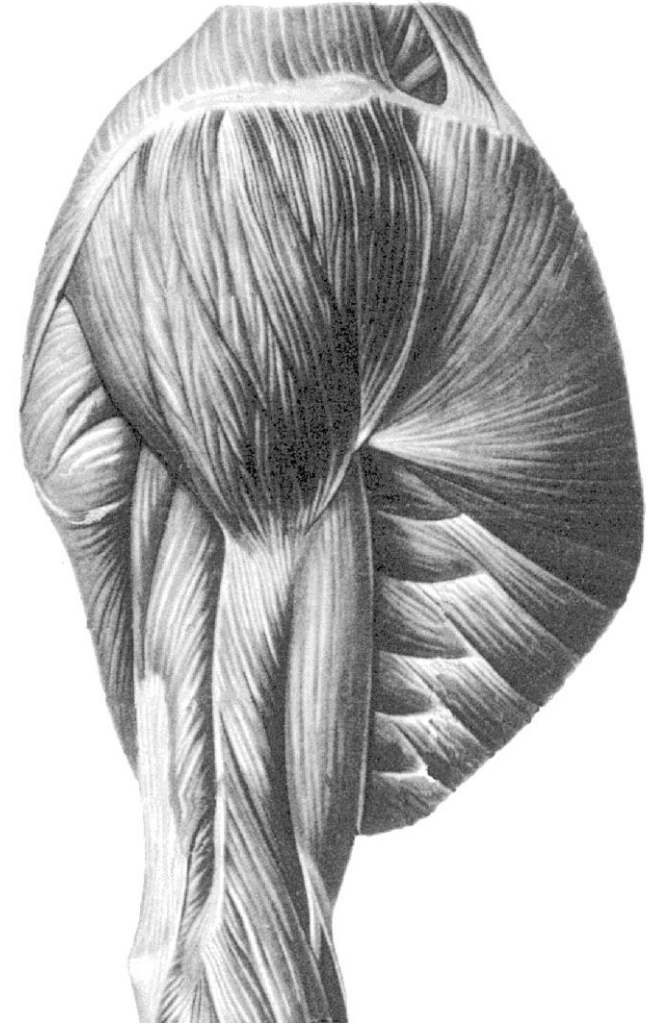
6. The muscles which adduct the upper arm: _____



**Superficial muscles of
back**

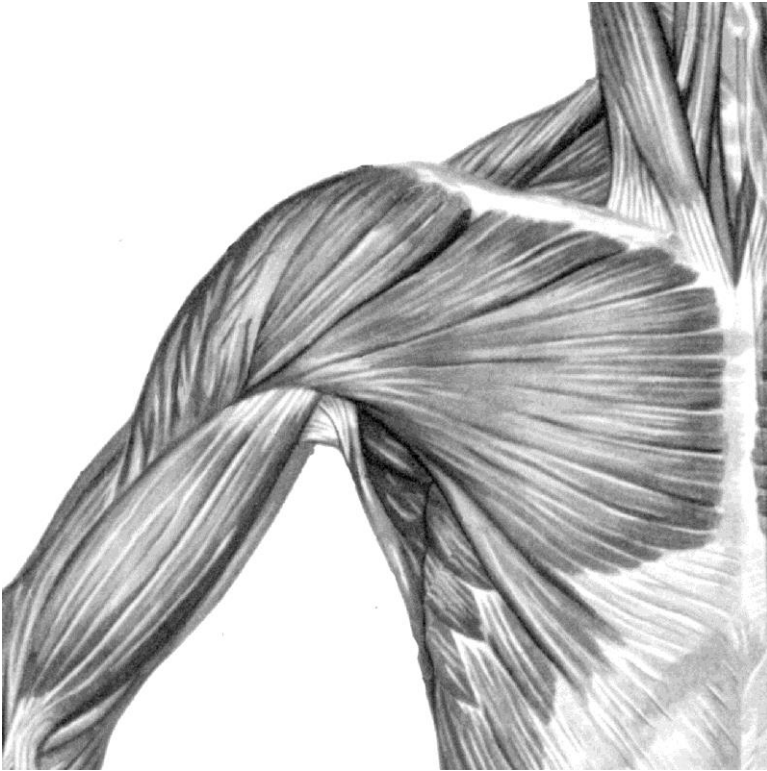


**Muscles of chest, shoulder
and arm
(anterior aspect)**



**Muscles of shoulder and
upper arm**

Task 7: Write the name of the muscles, which form the walls of the axillary cavity, and indicate the visible muscles in the picture:



**Muscles of shoulder and
upper arm
(lateral aspect)**

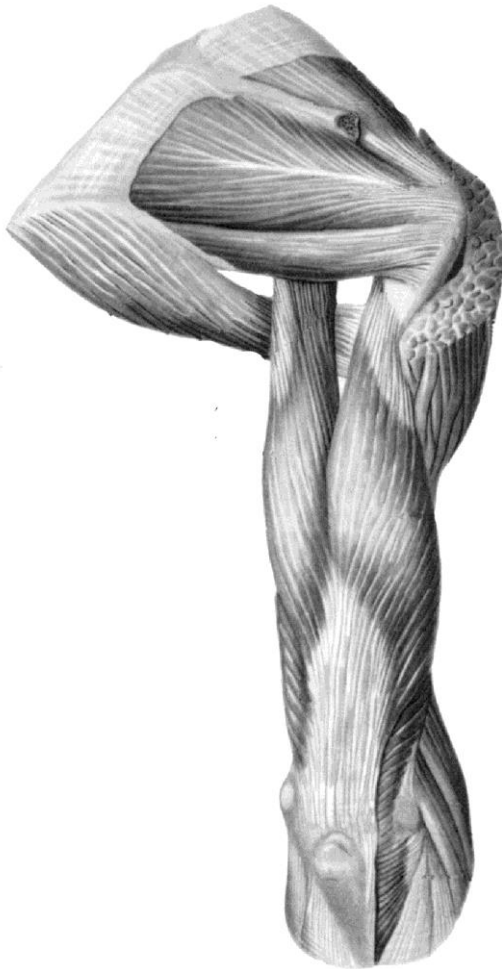
1. Anterior wall: _____

2. Posterior wall: _____

3. Medial wall: _____

4. Lateral wall: _____

Task 8: Indicate the quadrangular and triangular spaces in the picture, indicate the muscles, which bound them, write the names of these muscles and write the contents of both spaces:

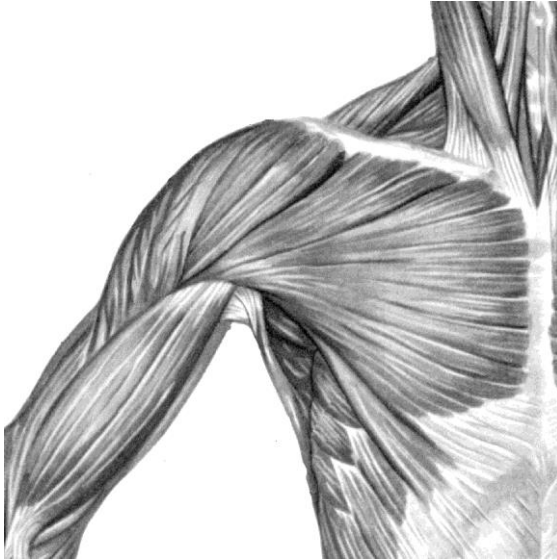


**Muscles of shoulder and
upper arm
(posterior aspect)**

1. The walls of the quadrangular space:
superior _____
inferior _____
lateral _____
2. The walls of the triangular space:
superior _____
inferior _____
lateral _____
medial _____
3. The content of the quadrangular space: _____

4. The content of the triangular space: _____

Task 9: Indicate the medial and lateral bicipital grooves in the picture and write their contents:



1. The content of the medial bicipital groove: _____

2. The content of the lateral bicipital groove: _____

Task 9: Write the names of the muscles which form the walls of the humeromuscular canal:

Muscles of chest, shoulder
and arm
(anterior aspect)

1. Anterior wall _____

2. Posterior wall _____

Task 11: Write the content of the humeromuscular canal: _____
