

## SELFTESTS: THE MUSCLES AND TOPOGRAPHY OF FOREARM AND HAND

**Task 1: Indicate the muscles of the anterior group of the antebrachial muscles in the following picture.**

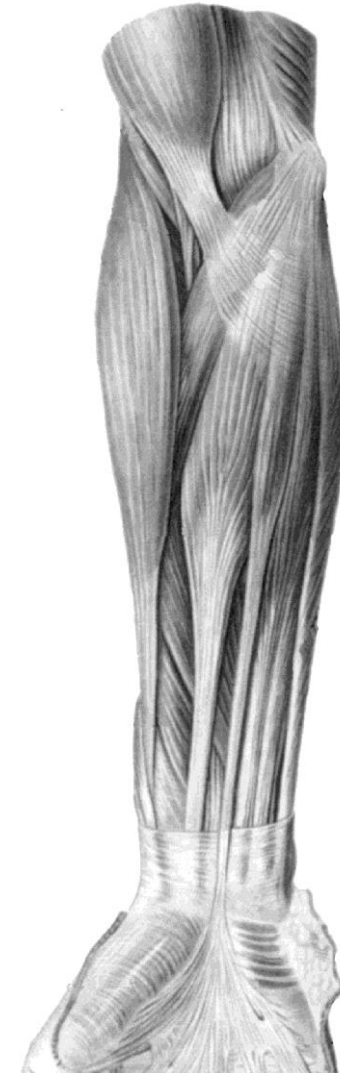1. Brachioradialis, *m. brachioradialis*;
2. Pronator teres, *m. pronator teres*;
3. Flexor carpi radialis, *m. flexor carpi radialis*;
4. Palmaris longus, *m. palmaris longus*;
5. Flexor digitorum superficialis, *m. flexor digitorum superficialis*;
6. Flexor carpi ulnaris, *m. flexor carpi ulnaris*;
7. Flexor pollicis longus, *m. flexor pollicis longus*;

**Task 2: Draw with color lines the boundaries of the cubital fossa.  
Indicate the muscles which bound the cubital fossa, in the picture,  
and write their names.**

**Task 3: Answer the question:**

What is the general action of the anterior antebrachial muscles?

---



**Muscles of forearm  
(anterior aspect)**

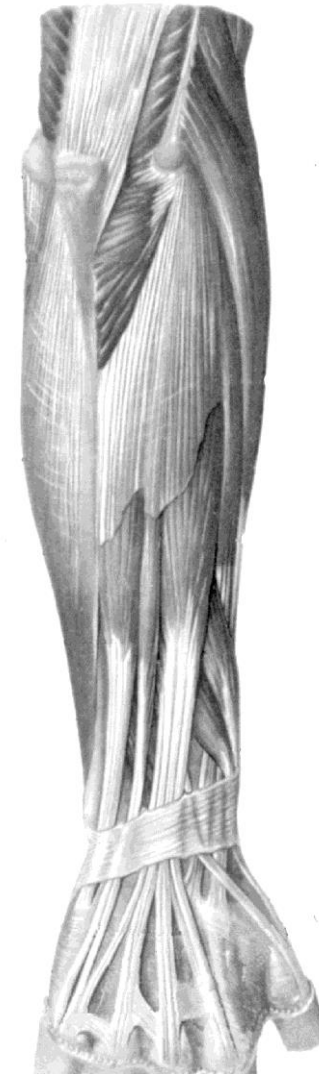**Task 4: Indicate the muscles of the posterior group of the antebrachial muscles in the following picture:**

1. Extensor carpi radialis longus, *m. extensor carpi radialis longus*;
2. Extensor carpi radialis brevis, *m. extensor carpi radialis brevis*;
3. Extensor digitorum, *m. extensor digitorum*;
4. Extensor digiti minimi, *m. extensor digiti minimi*;
5. Extensor carpi ulnaris, *m. extensor carpi ulnaris*;
6. Abductor pollicis longus, *m. abductor pollicis longus*;
7. Extensor pollicis brevis, *m. extensor pollicis brevis*;
8. Extensor pollicis longus, *m. extensor pollicis longus*;
9. Extensor indicis, *m. extensor indicis*.

**Task 5: Answer the question:**

What is the general action of the posterior antebrachial muscles?

---



**Muscles of forearm  
(posterior aspect)**

**Task 6: Write the names of the antebrachial muscles in accordance with their action:**

1. The muscles which flex the forearm at the elbow joint\_\_\_\_\_
2. The muscles which flex the hand at the wrist joint\_\_\_\_\_
3. The muscles which extend the hand at the wrist joint\_\_\_\_\_
4. The muscles which abduct the hand at the wrist joint\_\_\_\_\_
5. The muscles which adduct the hand at the wrist joint\_\_\_\_\_
6. The muscles which rotate (inward and outward) the forearm at the proximal radioulnar joint\_\_\_\_\_
7. The muscles which rotate (inward and outward) the forearm at the distal radioulnar joint \_\_\_\_\_

**Task 7: Draw with color lines the topographical grooves of the forearm (ulnar, radial and median) in the picture, indicate the muscles which bound them, and write their contents:**

The median groove contains: \_\_\_\_\_

\_\_\_\_\_

The radial groove contains: \_\_\_\_\_

\_\_\_\_\_

The ulnar groove contains: \_\_\_\_\_

\_\_\_\_\_

**Task 8: Indicate the projections of the carpal canals in the picture, and write their contents:**

The ulnar carpal canal contains: \_\_\_\_\_

\_\_\_\_\_

The radial carpal canal contains: \_\_\_\_\_

\_\_\_\_\_

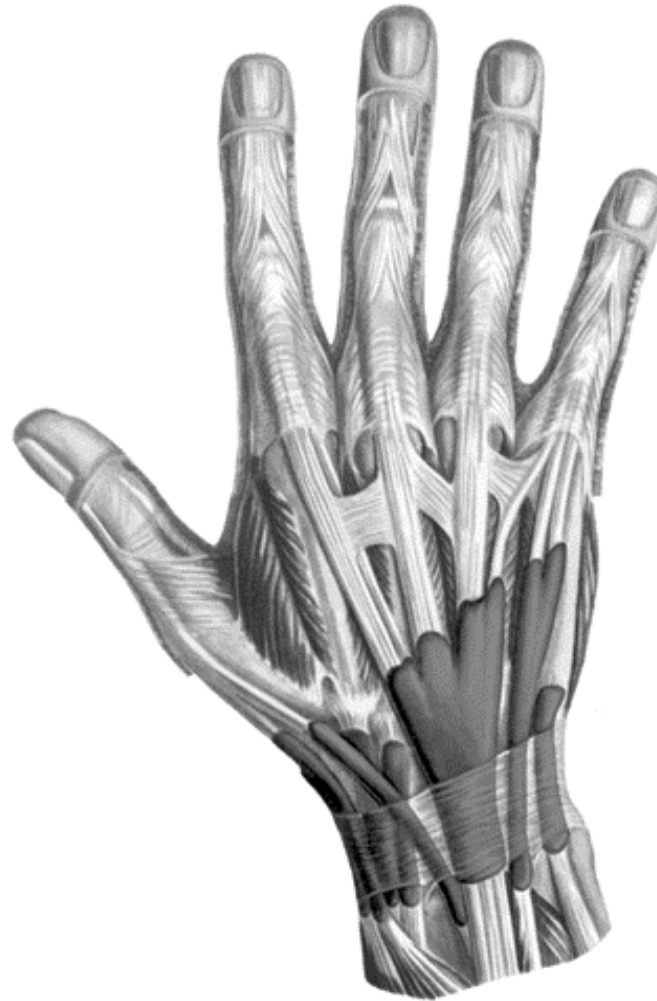The carpal canal contains: \_\_\_\_\_

\_\_\_\_\_



**Muscles of forearm**  
**(anterior aspect)**

**Task 9: Indicate the muscles, which belong to the tendons passing through the canals shown in the picture, and write their names.**



**Dorsal synovial sheaths of  
right hand**

**Task 10: Indicate the muscles of the hand in the picture:**

1. Abductor pollicis brevis, *m. abductor pollicis brevis*;
2. Flexor pollicis brevis, *m. flexor pollicis brevis*;
3. Opponens pollicis, *m. opponens pollicis*;
4. Adductor pollicis, *m. adductor pollicis*;
5. Palmaris brevis, *m. palmaris brevis*;
6. Abductor digiti minimi, *m. abductor digiti minimi*;
7. Flexor digiti minimi brevis, *m. flexor digiti minimi brevis*;
8. Opponens digiti minimi, *m. opponens digiti minimi*;
9. Lumbricales, *mm. lumbricales*;
10. Dorsal interossei, *mm. interossei dorsales*;

**Task 11: Write the names of the following muscles:**

Muscles of thenar \_\_\_\_\_

\_\_\_\_\_

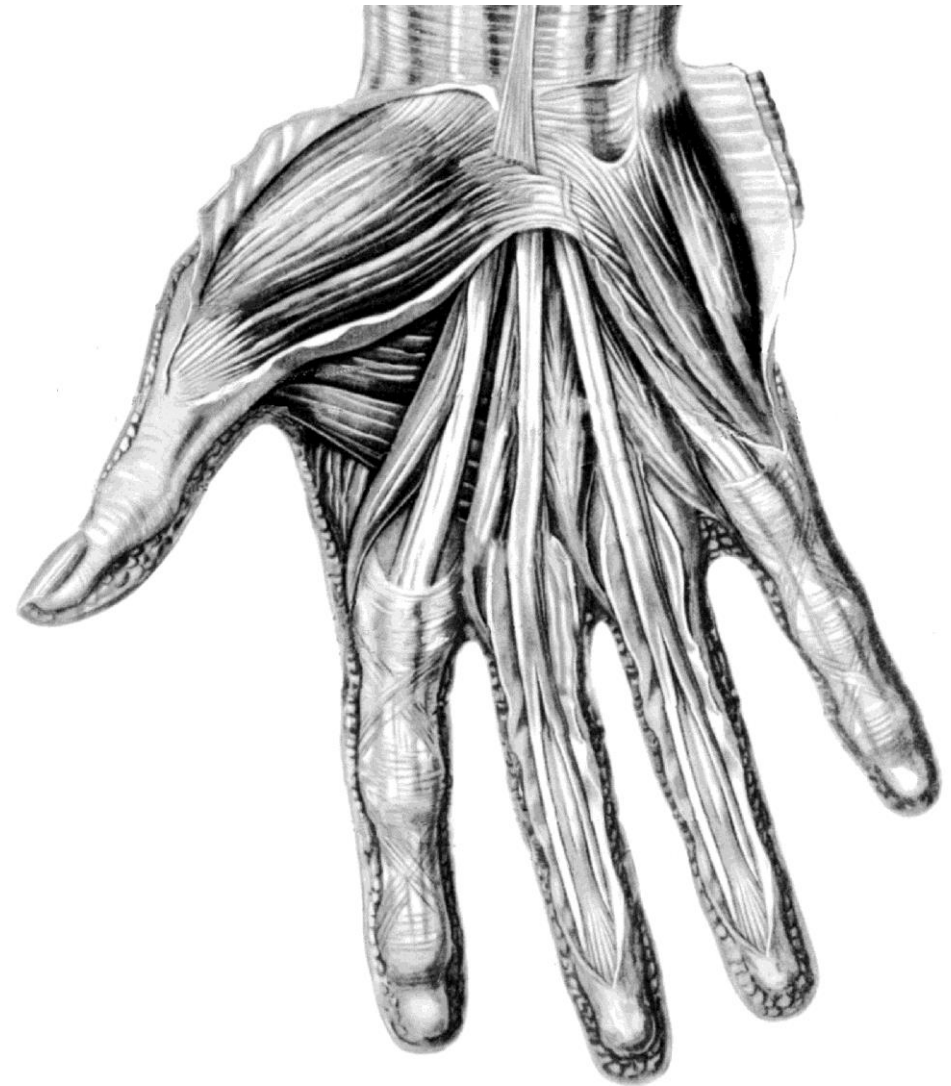
Muscles of  
hypothenar \_\_\_\_\_

\_\_\_\_\_

Middle muscles of the hand

\_\_\_\_\_

\_\_\_\_\_



**Muscles of hand  
(palmar aspect)**